

運動傷害報告— 手腕關節

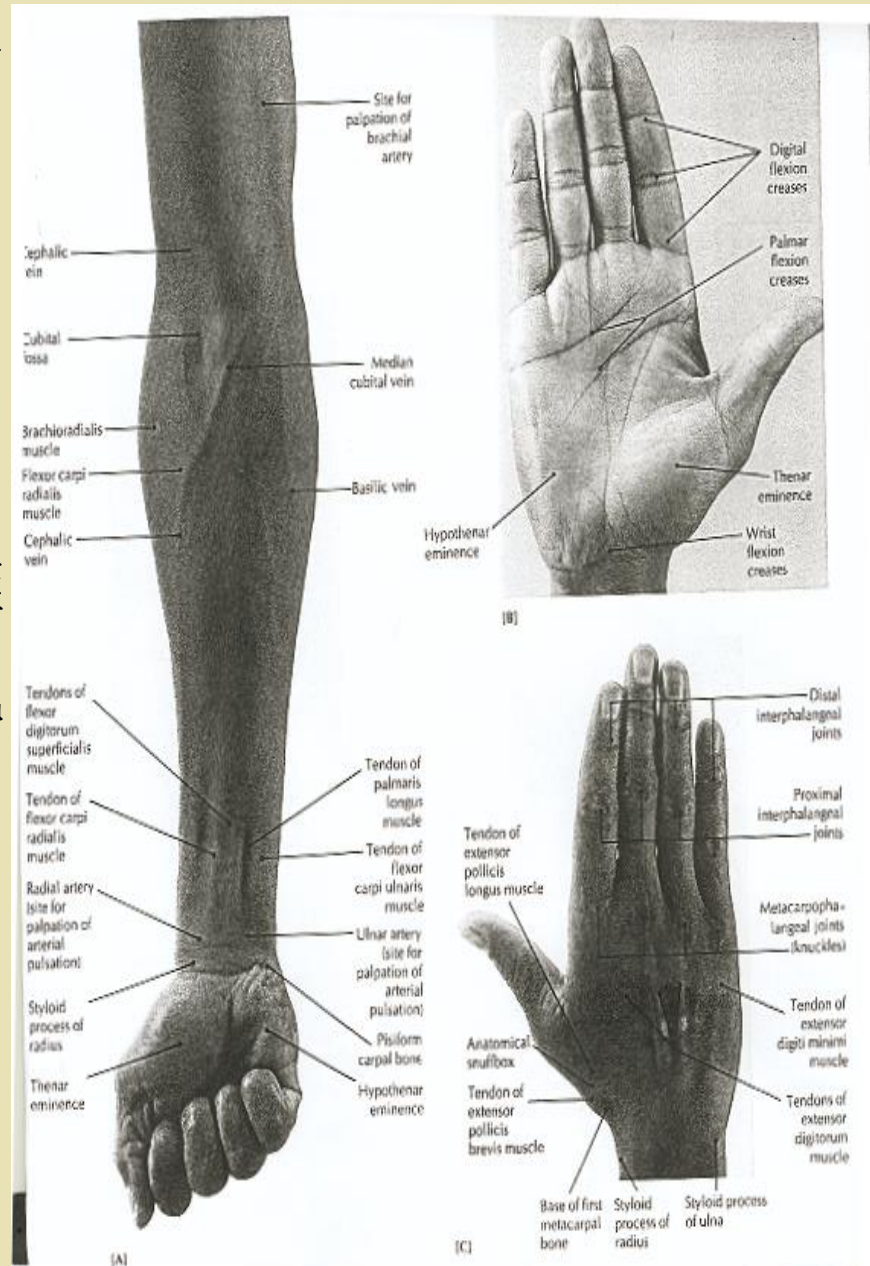


手腕關節特徵

- ◆ 手部關節包括橈腕關節、腕掌關節、掌指關節、指間關節等

特徵

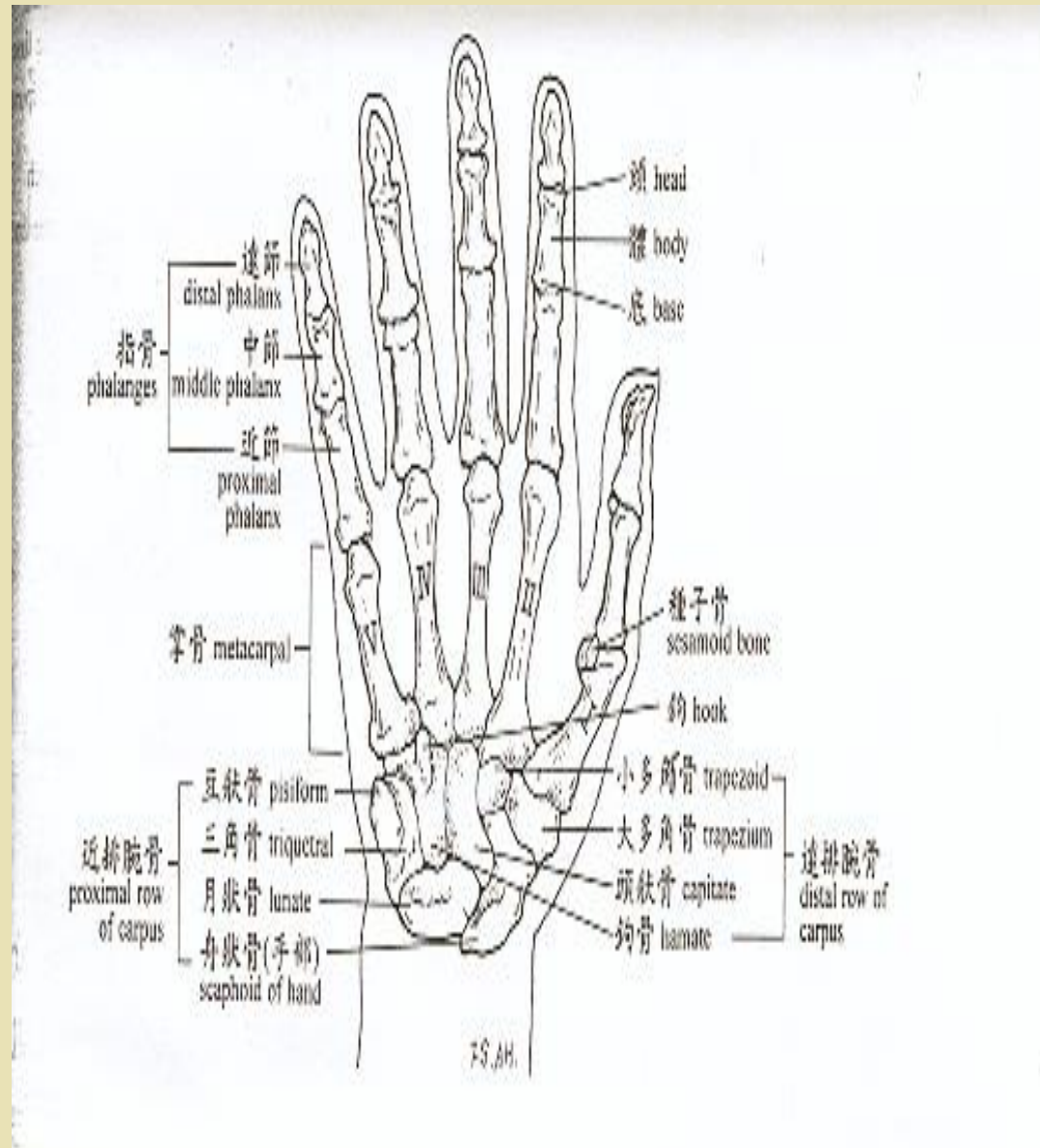
- ◆ 高度精細，結構複雜
- ◆ 由許多小骨頭及小肌肉構成
- ◆ 可執行精細工作
- ◆ 結構較脆弱
- ◆ 穩定度較差



腕關節的構造——骨骼部分(二)

腕骨

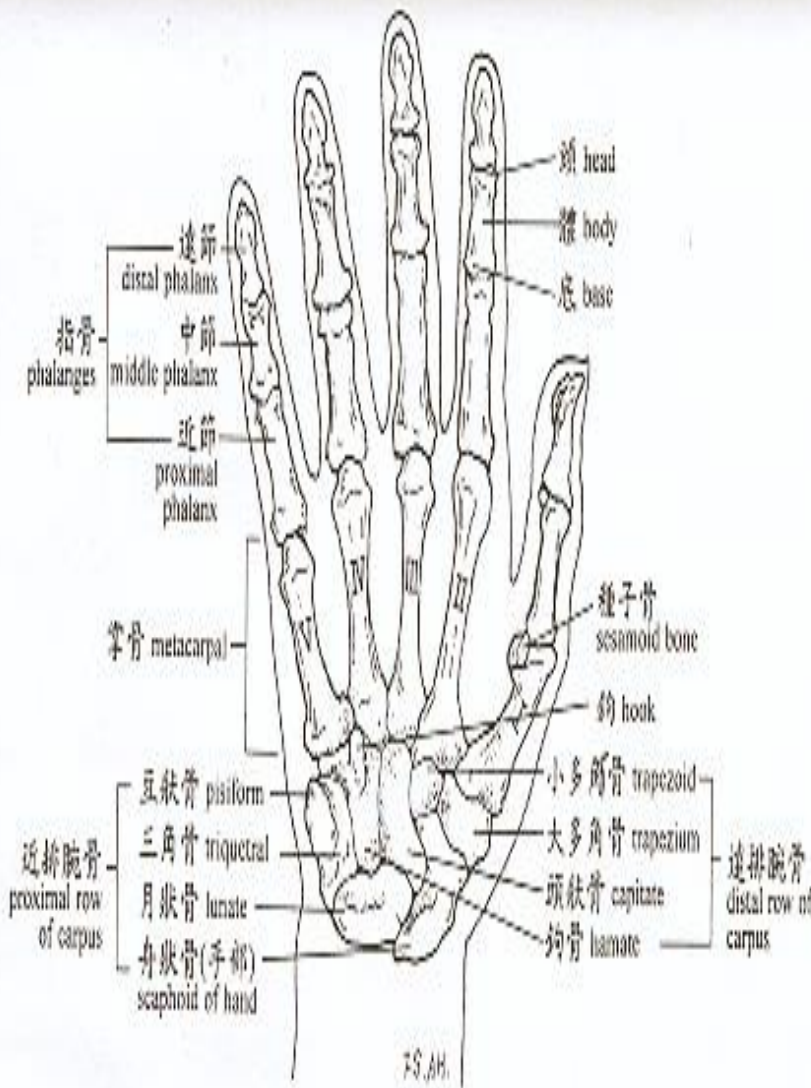
- ◆ 由上下兩排八塊骨組成，近心端由外到內依序為：
- ◆ 舟狀骨 (scaphoid)
- ◆ 月狀骨 (lunate)
- ◆ 三角骨 (triquetral)
- ◆ 豌豆骨 (pisiform)



腕關節的構造—骨骼部分(三)

腕骨

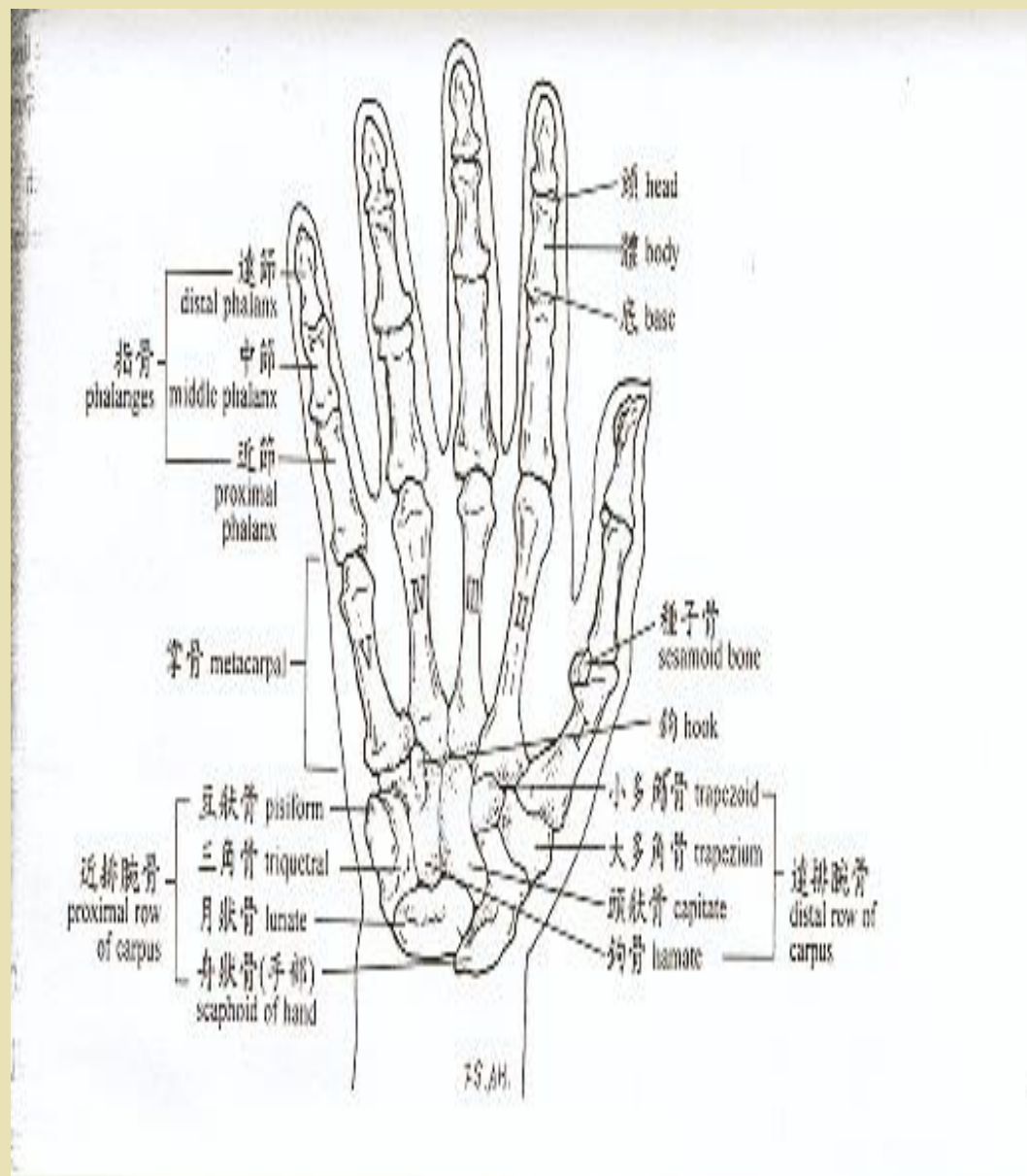
- ◆ 遠心端由外而內依序為：
- ◆ 大多角骨 (trapezium)
- ◆ 小多角骨 (trapezoid)
- ◆ 頭狀骨 (capitate)
- ◆ 鉤骨 (Hamate)



腕關節的構造—骨骼部分(四)

掌骨

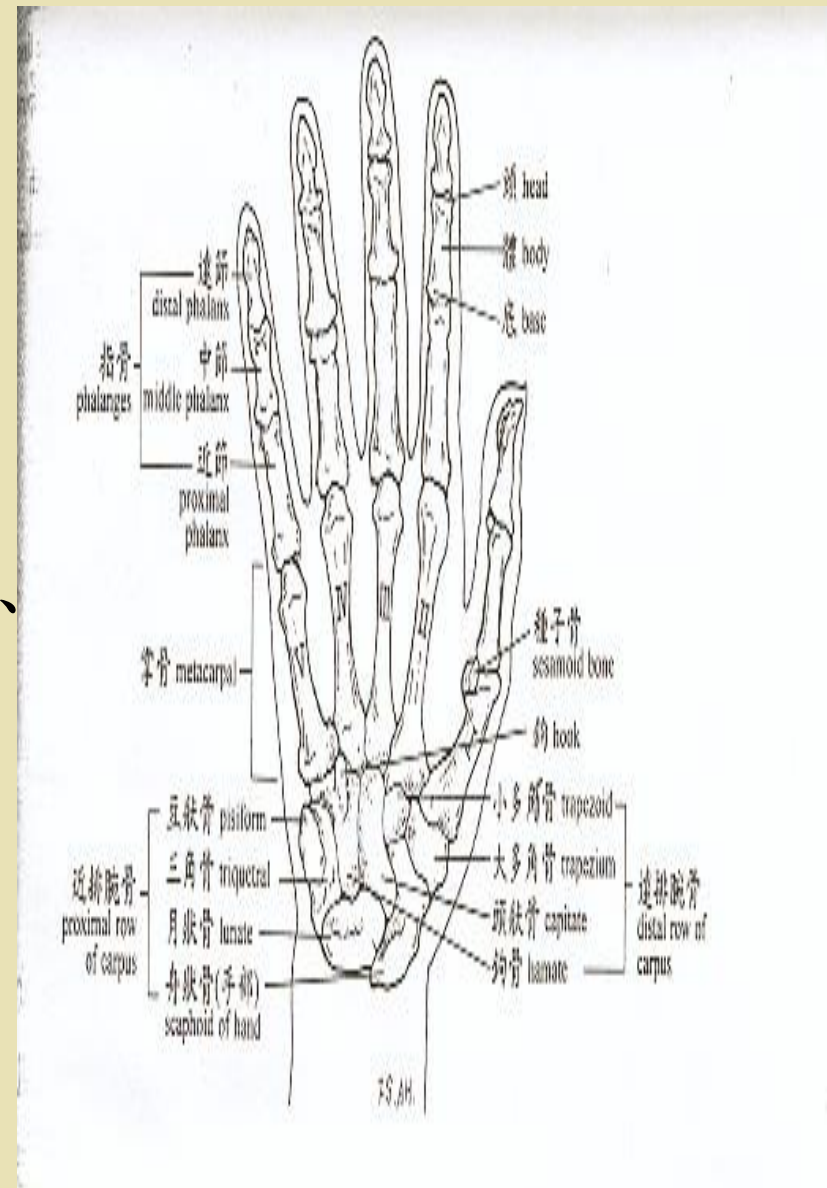
- 1.手掌由五塊掌骨所組成
- 2.每一塊掌骨含有基部
- 3.基部形成關節與指節



腕關節的構造—骨骼部分(五)

指骨

- ◆ 每隻手有14塊，每一塊含有一近側基部、骨幹、和遠側頭部。
- ◆ 除拇指外，其他手指都有三節指頭，細分為第一列(近側列)、第二列(中間列)、第三列(遠側列)。



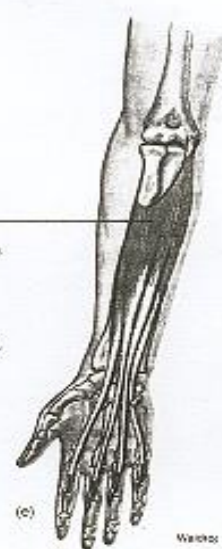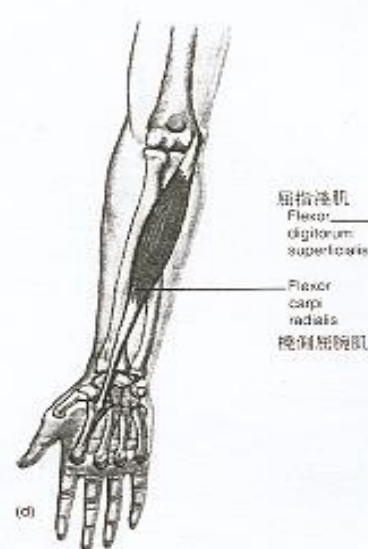
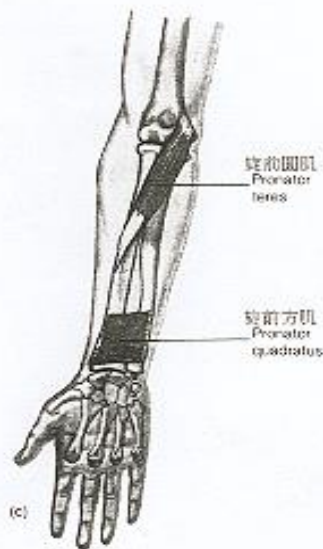
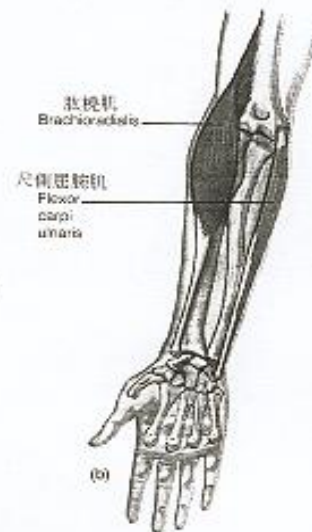
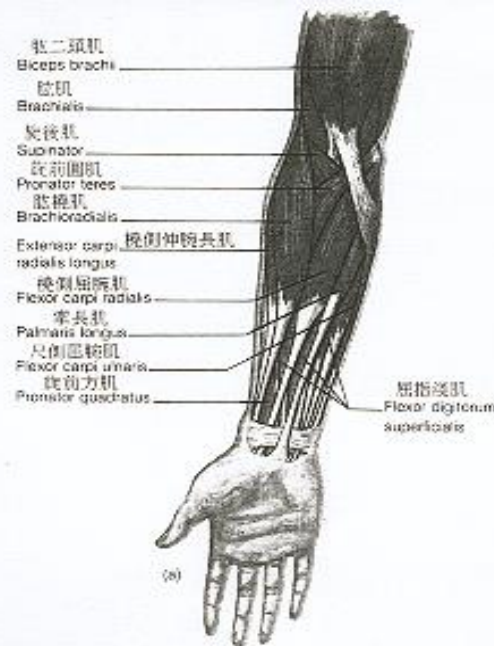
腕關節的構造—肌肉部分(一)

屈腕肌群(flexors)

- ◆ 橈側屈腕肌 (flexor carpi radialis)

- ◆ 掌長肌(palmaris)

- ◆ 尺側屈腕肌 (flexor carpi ulnaris)



腕關節的構造—肌肉部分(二)

伸腕肌(extensors)

- ◆ 橈側伸腕長肌 (extensor carpi radialis longus)
- ◆ 橈側伸腕短肌 (extensor carpi radialis brevis)
- ◆ 尺側伸腕肌 (extensor carpi ulnaris)

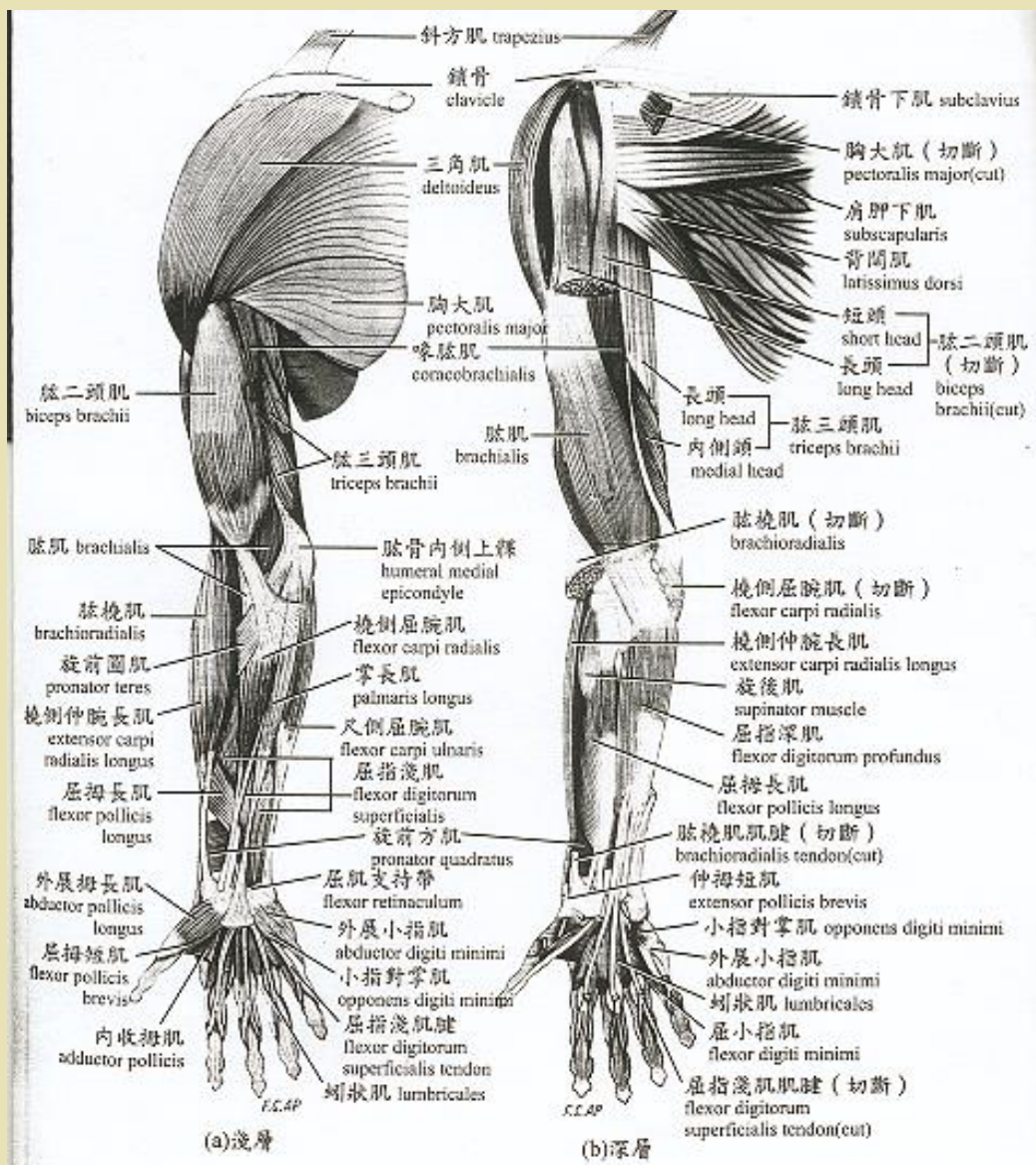



圖 8-7 上肢肌肉 (右手前面觀)



腕關節的構造—肌肉部分(三)

手掌內在肌肉群


- ◆ 蚓狀肌(Lumbrical Muscles)
- ◆ 骨間肌(The Interossei)
- ◆ 掌側骨間肌(Palmar Interossei)
- ◆ 背側骨間肌(Dorsal Interossei)

腕關節的構造—肌肉部分(四)

拇指之外在肌肉群

- ◆ 伸拇長肌(extensor pollicis longus)
- ◆ 伸拇短肌(extensor pollicis brevis)
- ◆ 拇指外展長肌(abductor pollicis longus)
- ◆ 屈拇長肌(flexor pollicis longus)






腕關節的構造—肌肉部分(五)

小指球肌肉群

- ◆ 小指球(Hypothenar eminece)
- ◆ 外展小指肌(Abductor Digiti Minimi)
- ◆ 屈小指肌(Flexor Digiti Minimi)
- ◆ 對掌小指肌(Opponens Digiti Minimi)



腕關節的構造—肌肉部分(六)

手部外來肌群(手掌前方及手掌背面)

- ◆ 屈指淺肌(*flexor digitorum superficialis*)
- ◆ 屈指深肌(*flexor digitorum profundus*)
- ◆ 伸指肌(*extensor digitorum*)
- ◆ 伸食指肌(*extensor indicis*)
- ◆ 伸小指肌(*extensor digitorum minimi*)

腕關節的構造—肌腱部分(一)

- ◆ 手指背部由伸指肌肌腱為主，並有背側骨間肌及蚓狀肌的肌腱連結，(伸指肌腱蓋)
- ◆ 手腕肌腱與手指關節構成機械構造及滑輪系統
- ◆ 一隻手可分為五滑輪

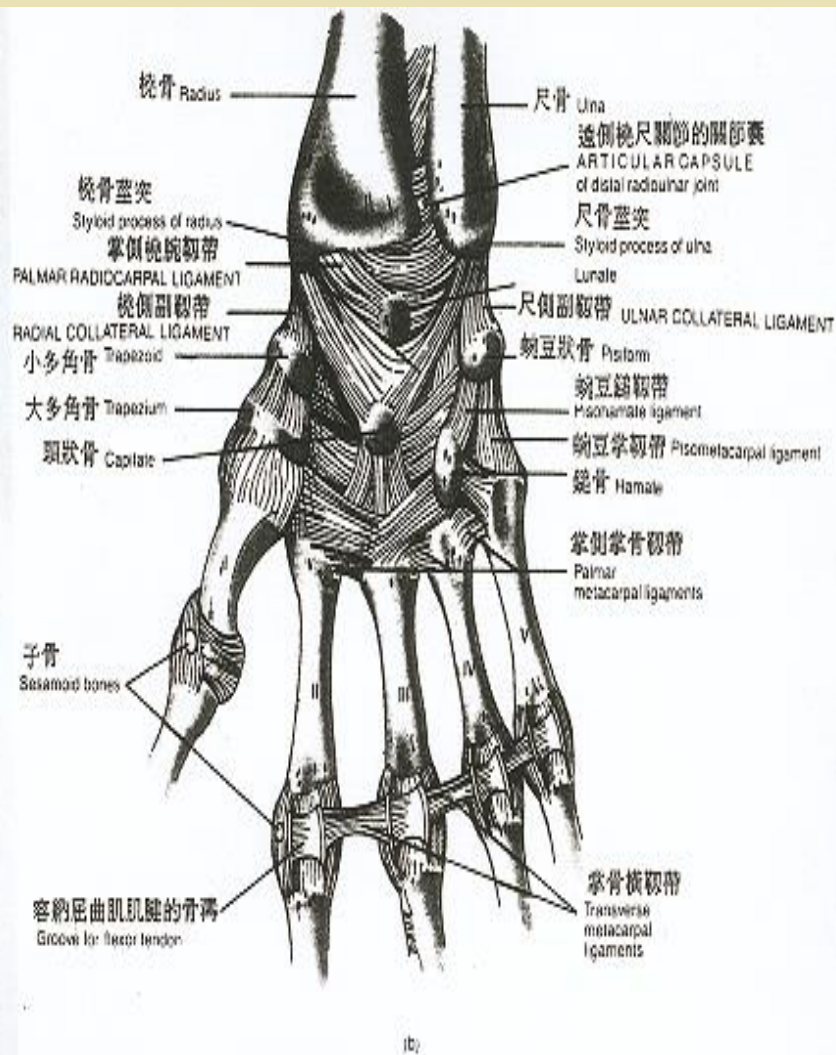
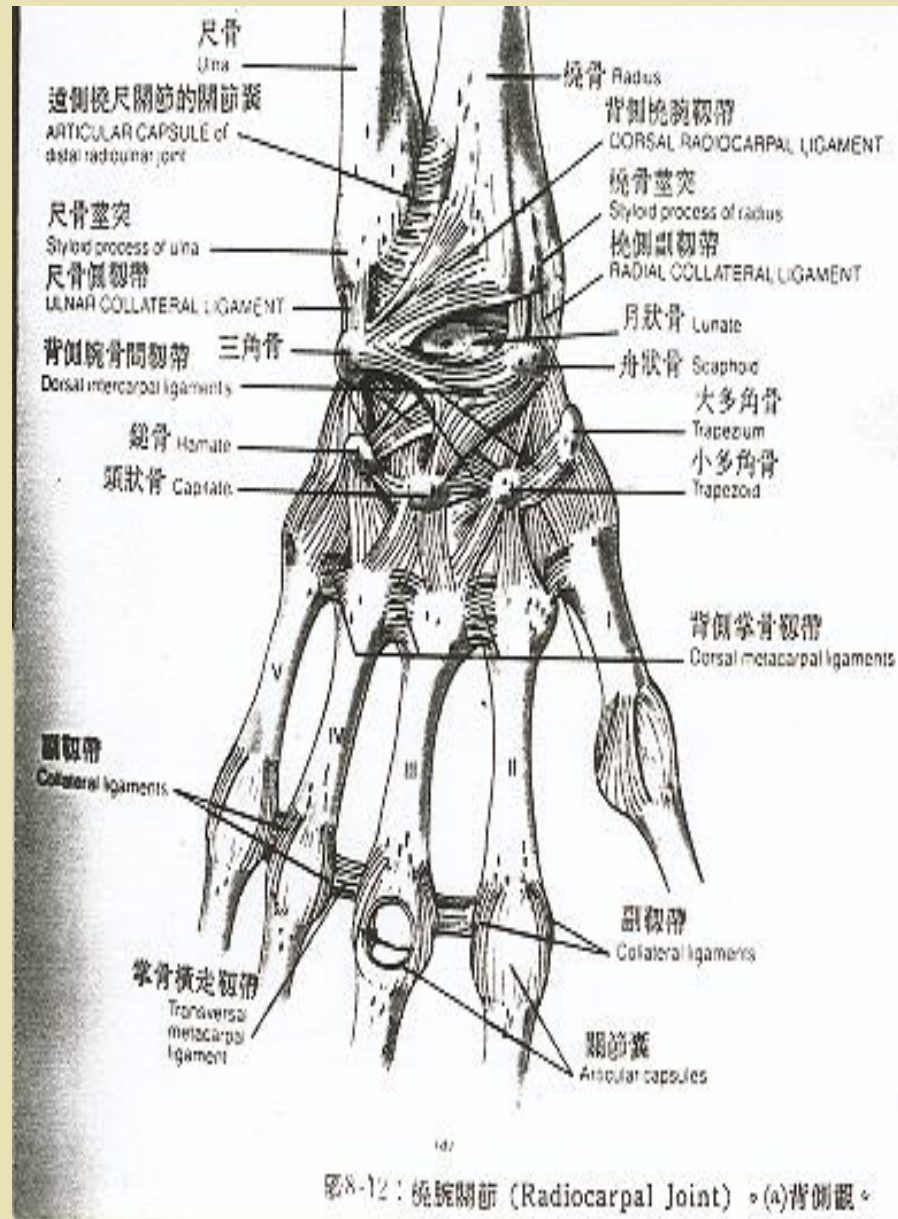


圖8-12：(橫)腕關節。(b)掌側觀。

腕關節的構造—肌腱部分(二)

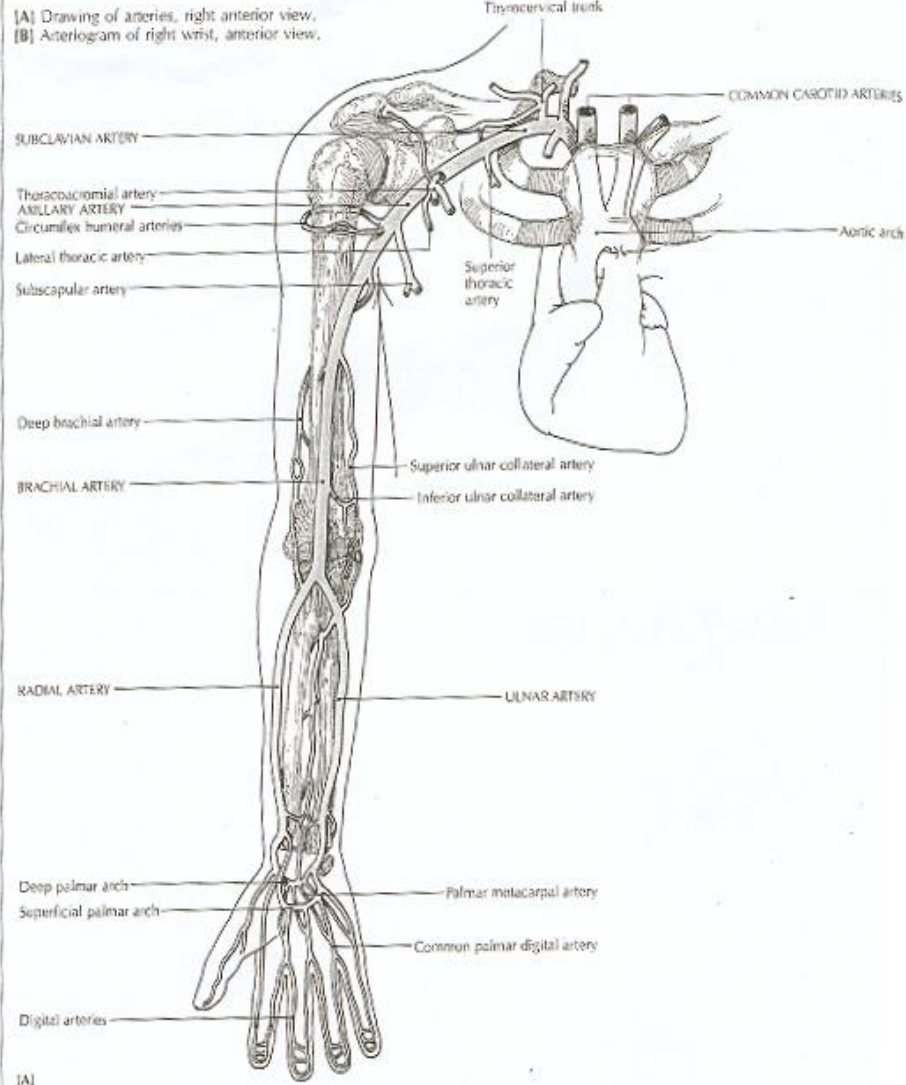
- ◆ 掌指關節
- ◆ 近心端指關節
- ◆ 遠心端指關節
- ◆ 近心骨關節
- ◆ 中間骨關節



腕關節構造—血管部分(動脈)

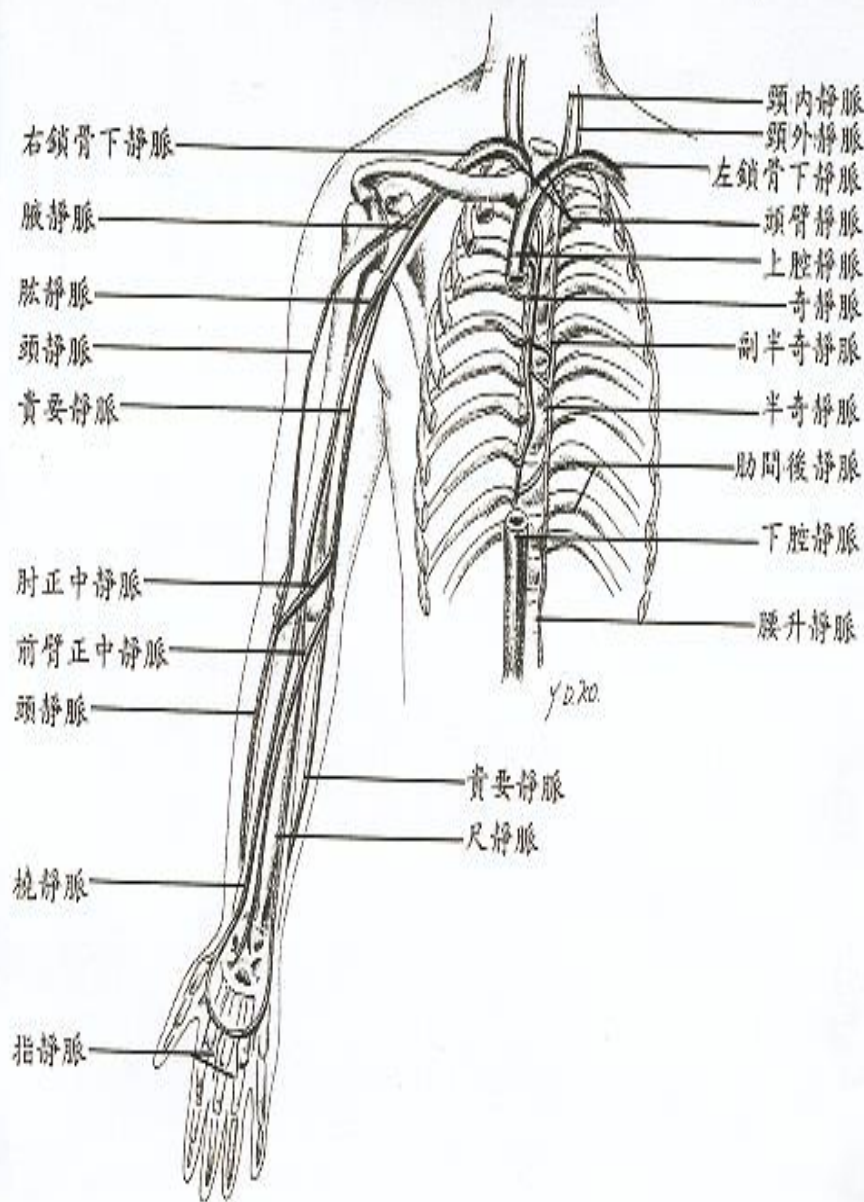
- ◆ 橈動脈(r
- ◆ adial artery)
- ◆ 尺動脈(ulnar artery)
- ◆ 深掌弓動脈(deep palmar arch)
- ◆ 淺掌弓動脈 (superficial palmar arch)
- ◆ 指動脈(digital arteries)


FIGURE 20.14 MAJOR ARTERIES OF THE UPPER LIMB



腕關節構造—血管部分(靜脈)

- ◆ 橈靜脈(radial vein)
- ◆ 尺靜脈(ulnar vein)
- ◆ 指靜脈(digital vein)
- ◆ 肘正中靜脈
(medial cubital vein)
- ◆ 頭靜脈(cephalic vein)





腕關節構造—神經部分

- ◆ 橈神經(radial nerve)
- ◆ 尺神經(ulnar nerve)
- ◆ 中央神經(median nerve)
- ◆ 指神經(digital nerve)

A collection of personal items is arranged on a light-colored surface. On the left, a portion of a chessboard with a blue and brown checkered pattern is visible, featuring several chess pieces. Below the chessboard are two medals: one with a red ribbon and a white star, and another with a blue ribbon and a white star. A pair of gold-rimmed glasses with thin temples lies horizontally across the middle. In the bottom left corner, a circular compass with a white face and black markings is partially visible.

下一個會更好.....

敬請期待.....