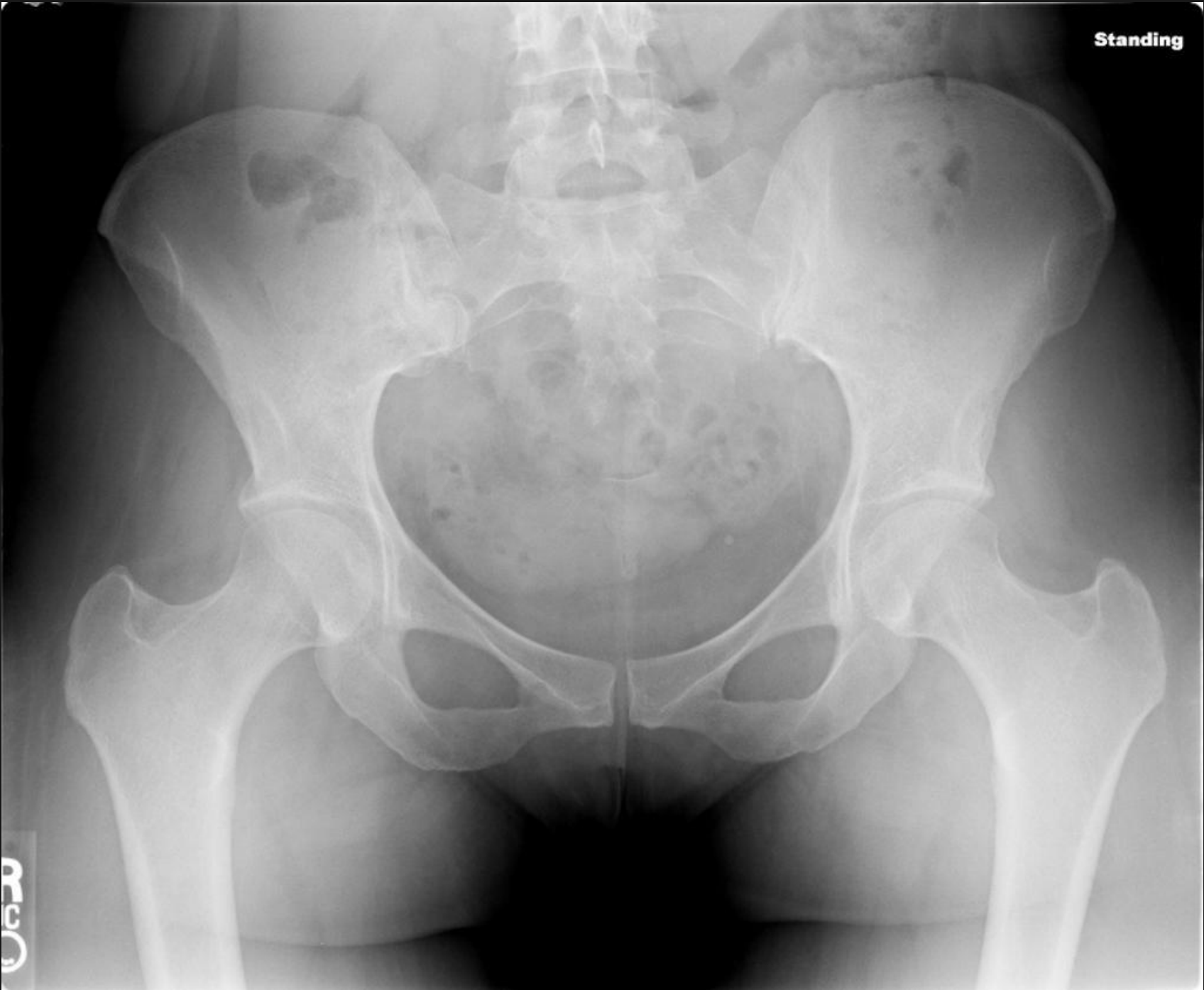
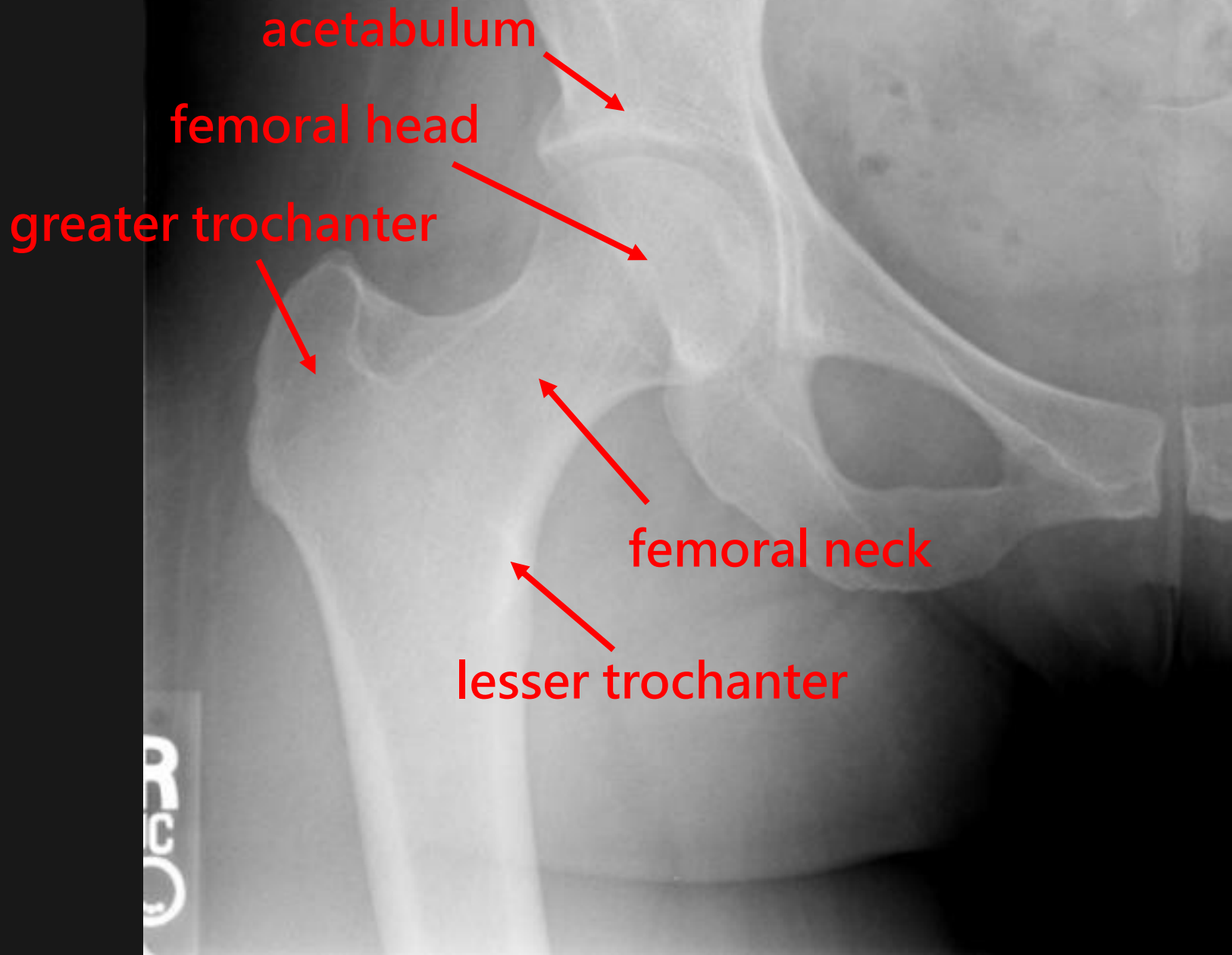


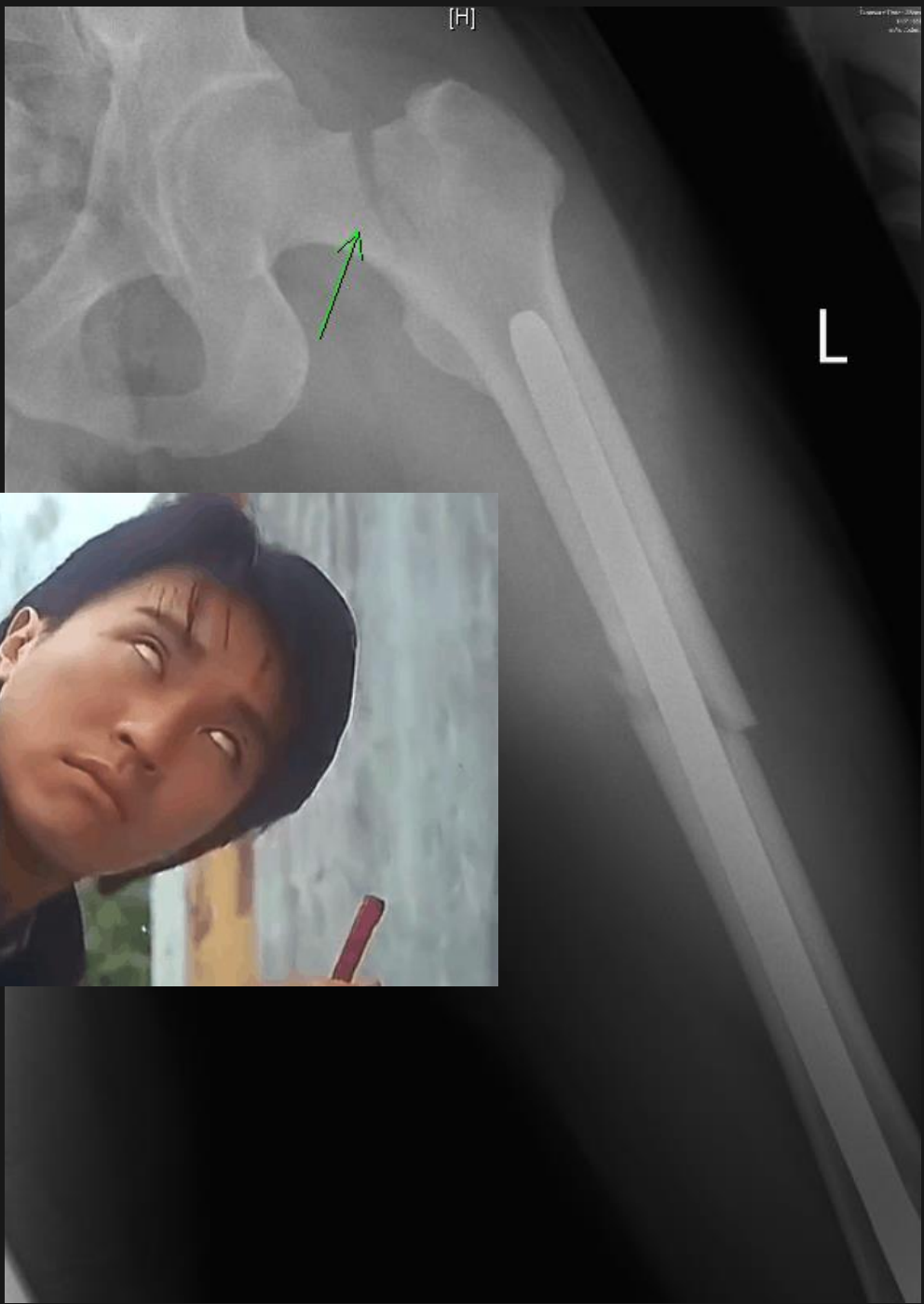
下肢影像學判讀

Standing

0520



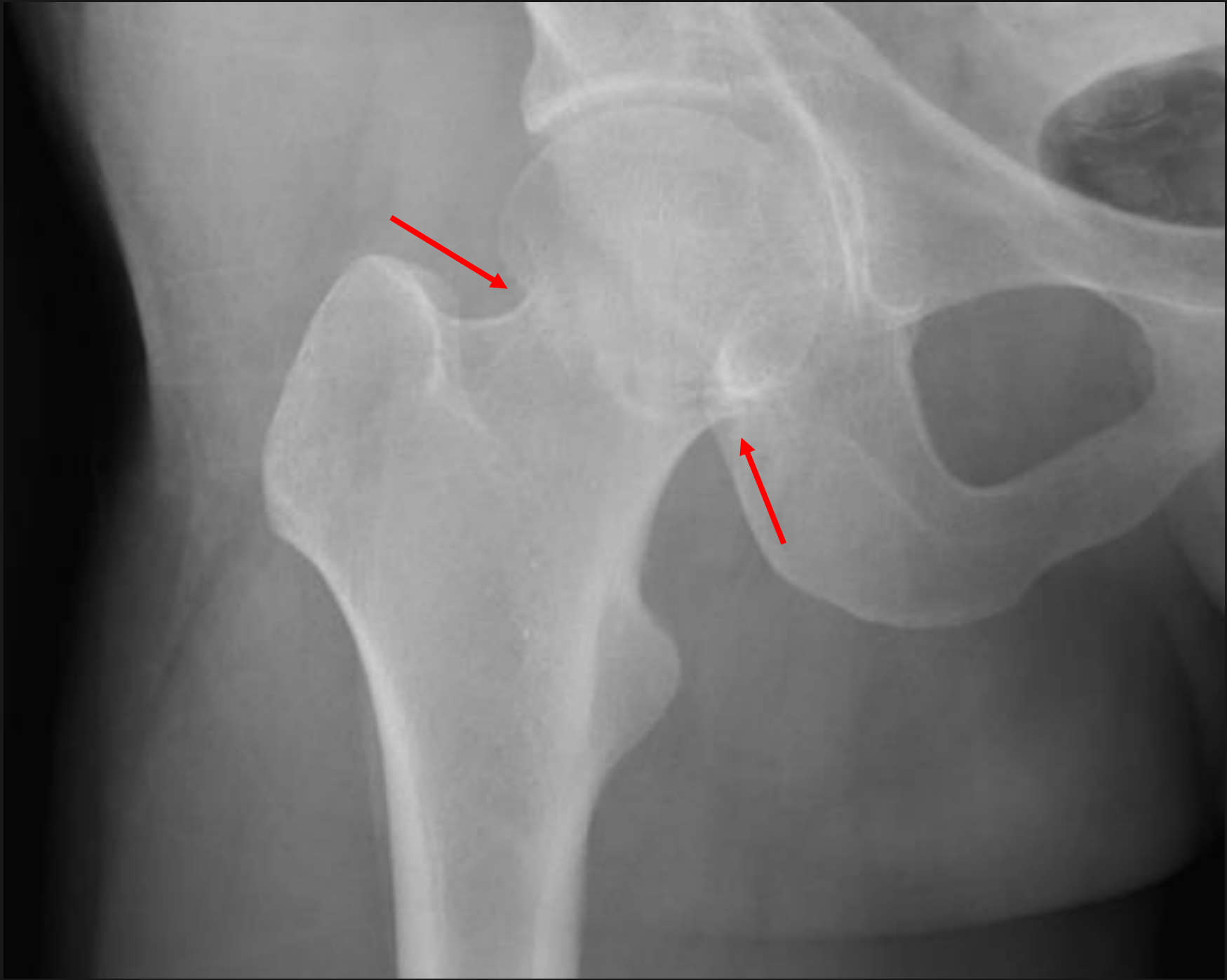




[H]
2018-07-28 (急診):
29歲男性，打球摔落右髌部疼痛，跛行

R





[H]

SHU SHENG HUC
Study Date: 2018/7/16
Study Time: 下午 03:42:36
MRN: 23974918

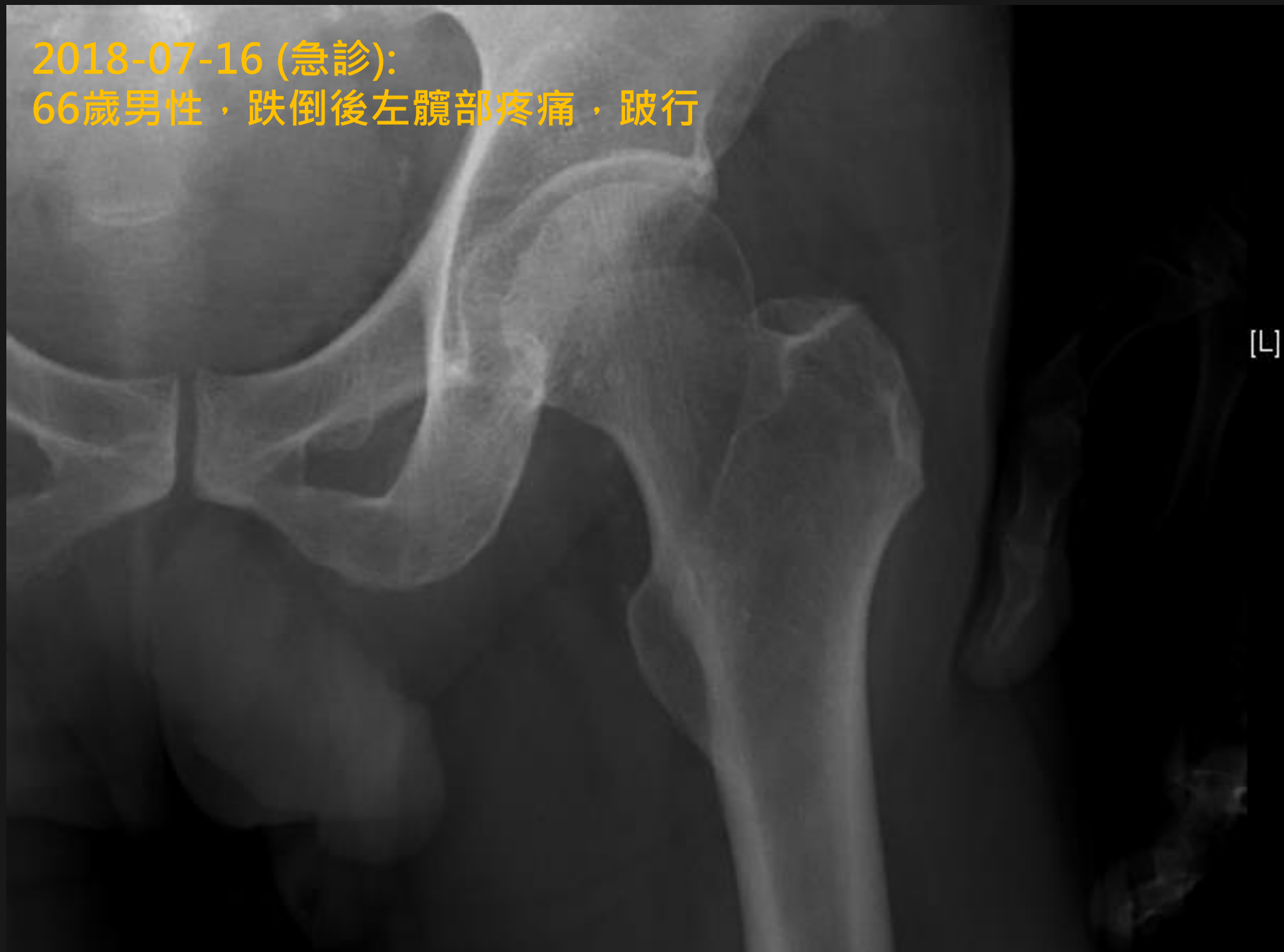2018-07-16 (急診):
66歲男性，跌倒後左髖部疼痛，跛行

R

L

[F]

2018-07-16 (急診):
66歲男性，跌倒後左腕部疼痛，跛行



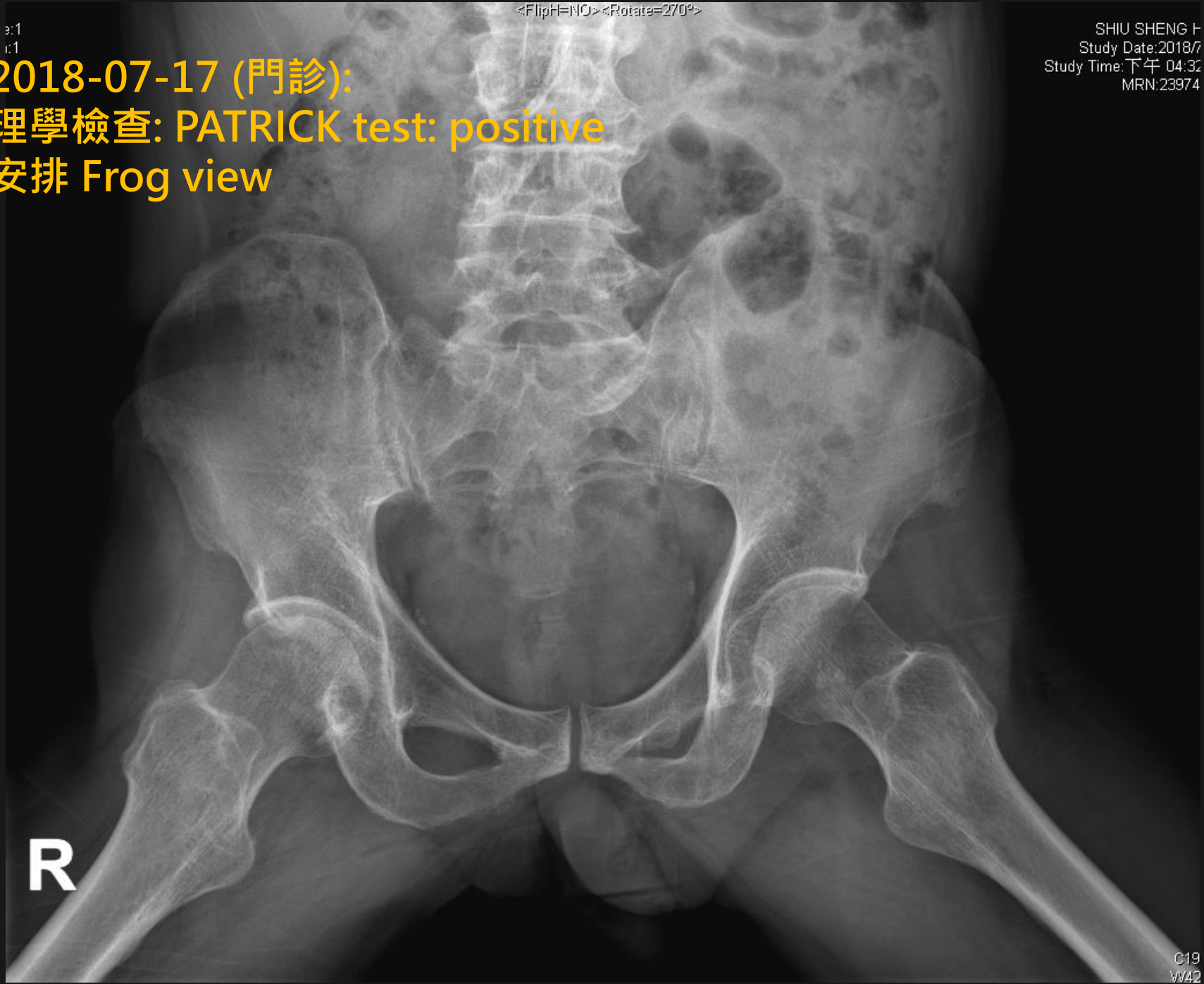
[L]

<FlipH=NO><Rotate=270°>

SHIU SHENG F
Study Date: 2018/7
Study Time: 下午 04:32
MRN: 23974

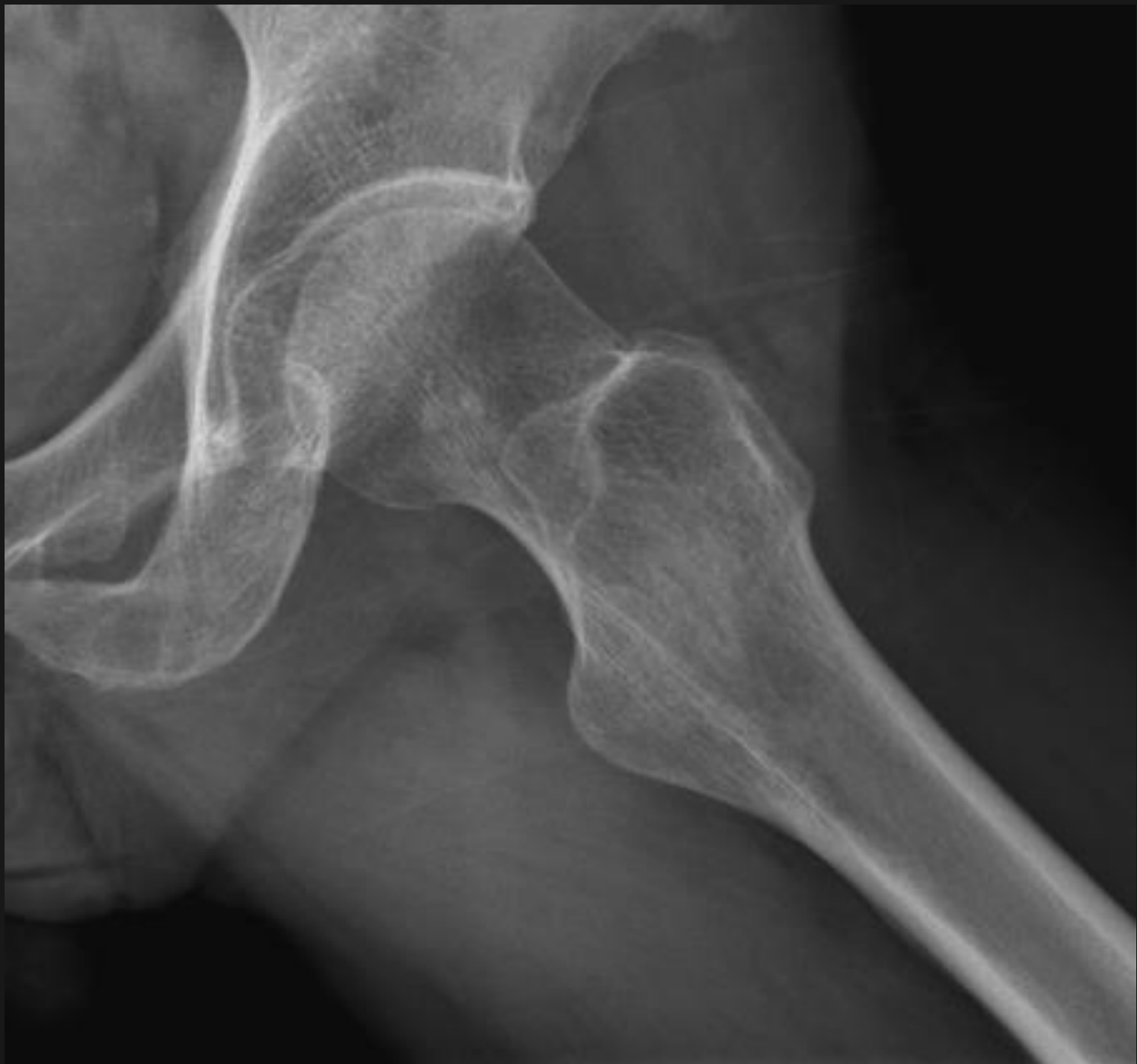s:1
r:1

2018-07-17 (門診):
理學檢查: PATRICK test: positive
安排 Frog view

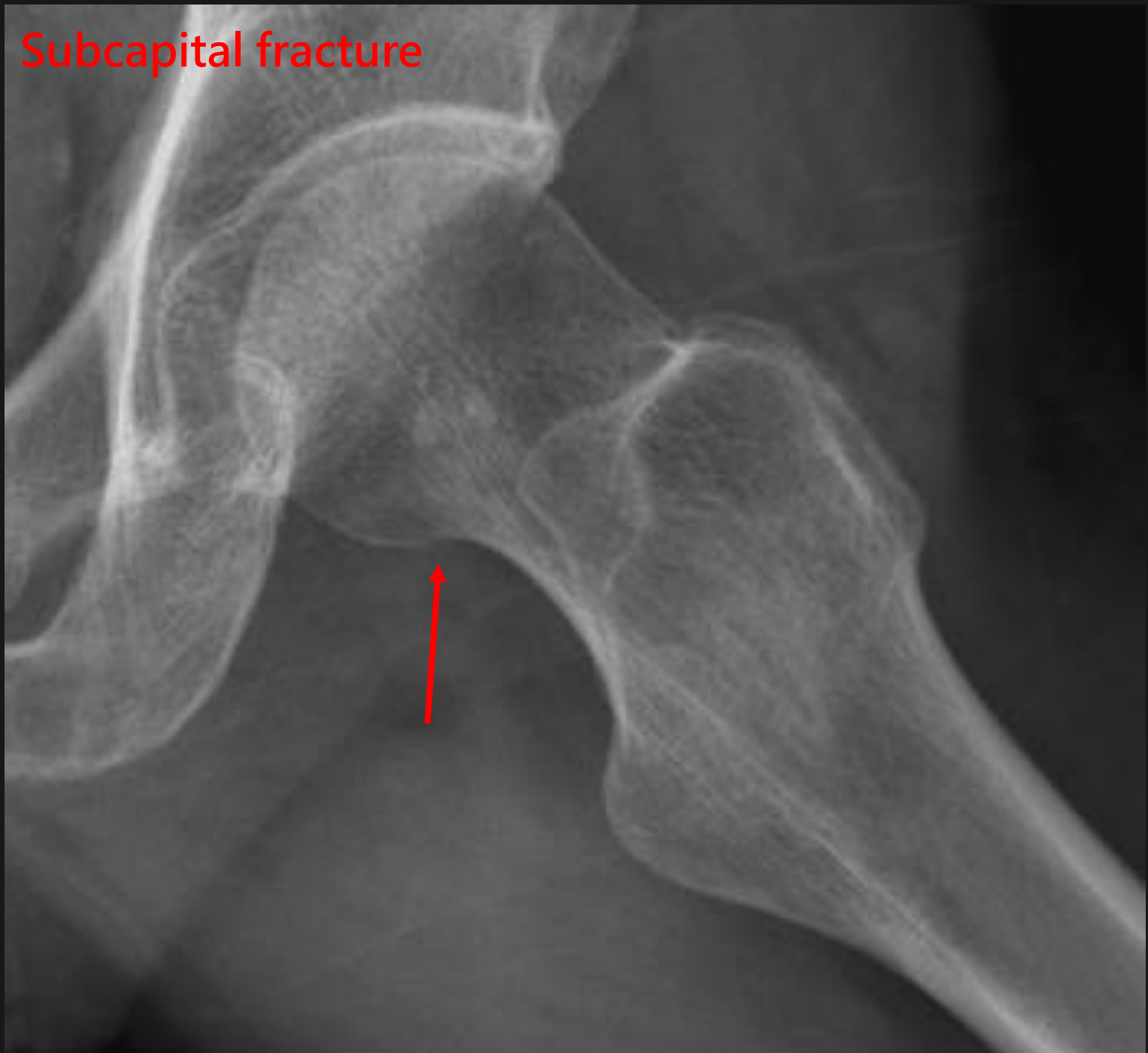


R

C19
VV42



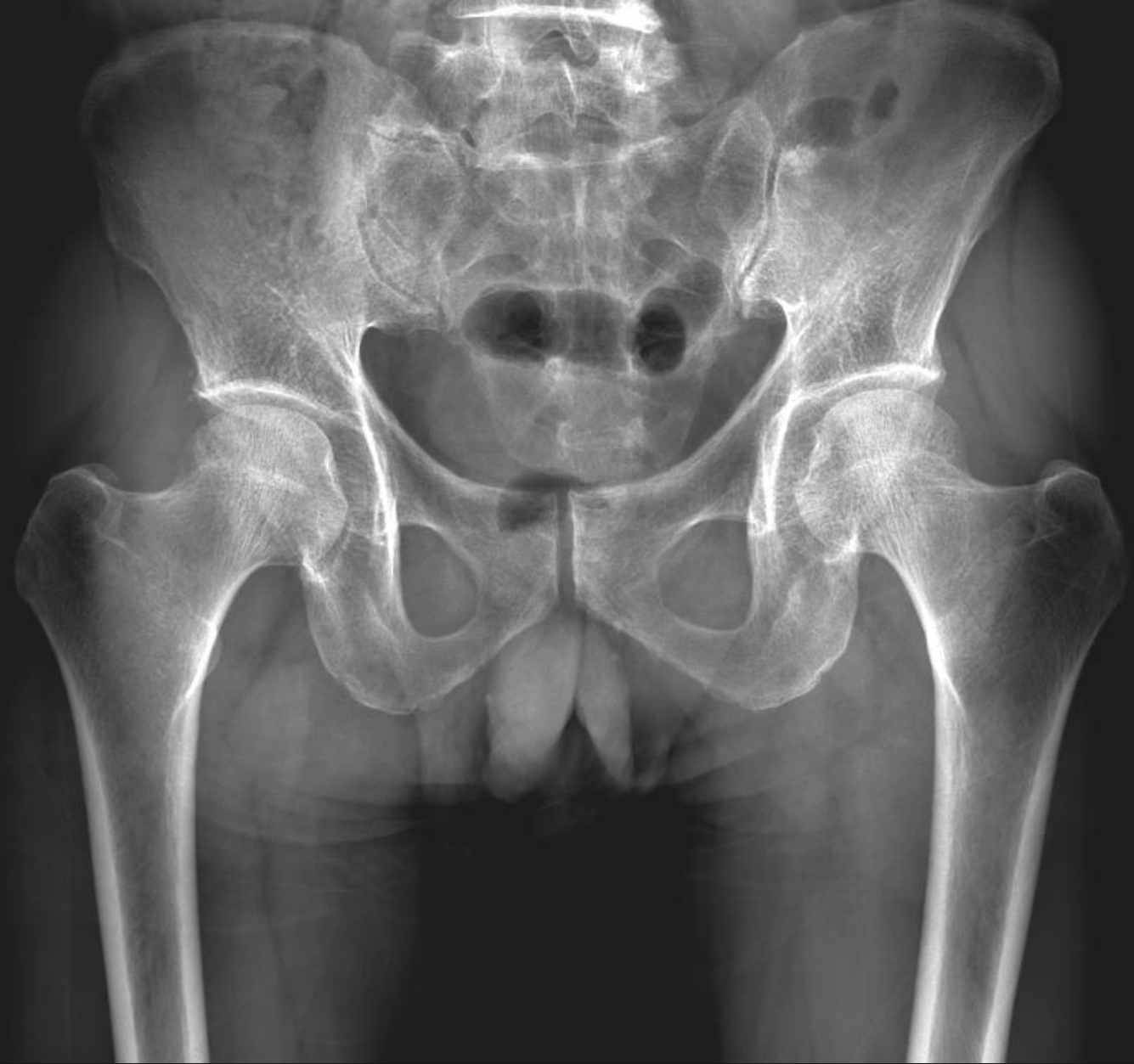Subcapital fracture



<Flip=NO><Rotate=270°>

HUANG
Study I
Study Time:

2018-08-28 (門診):
63歲男性，三個禮拜前跌倒後右髌部疼痛，跛行



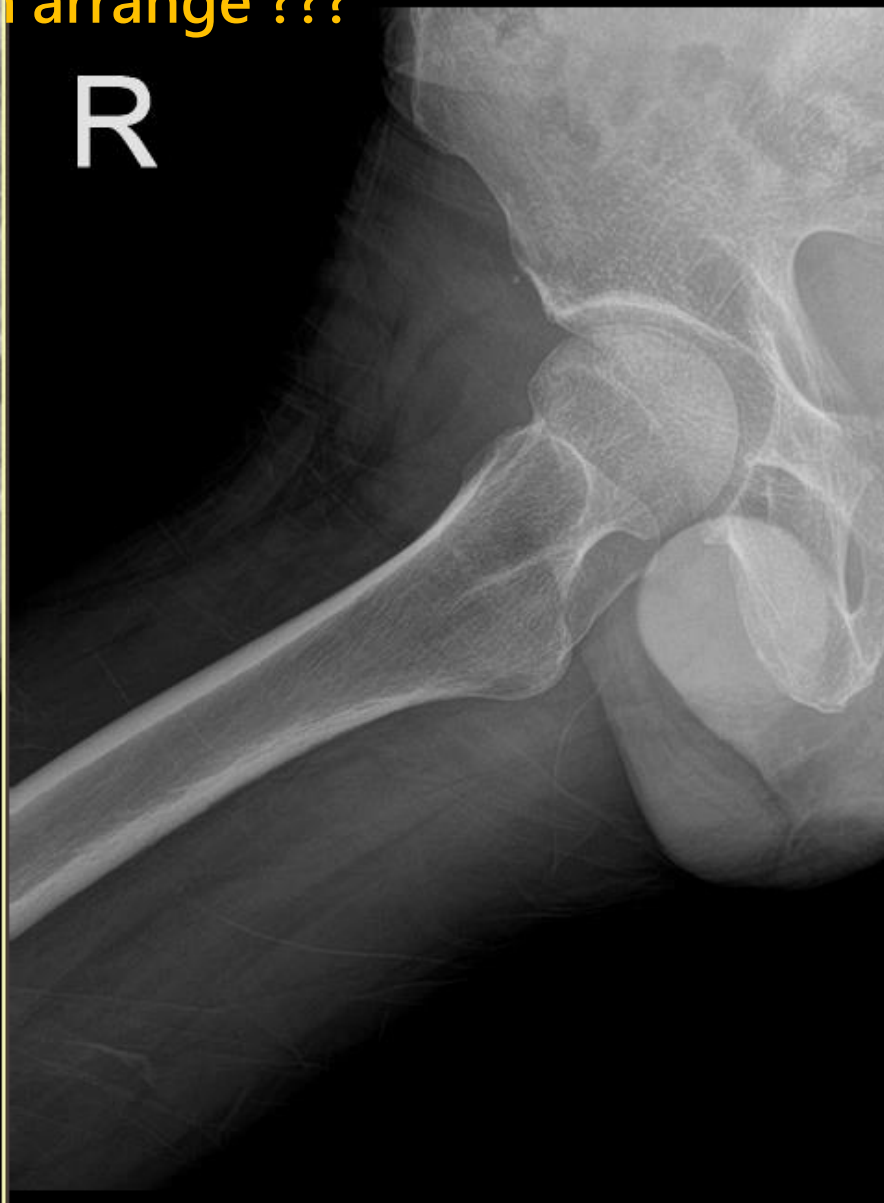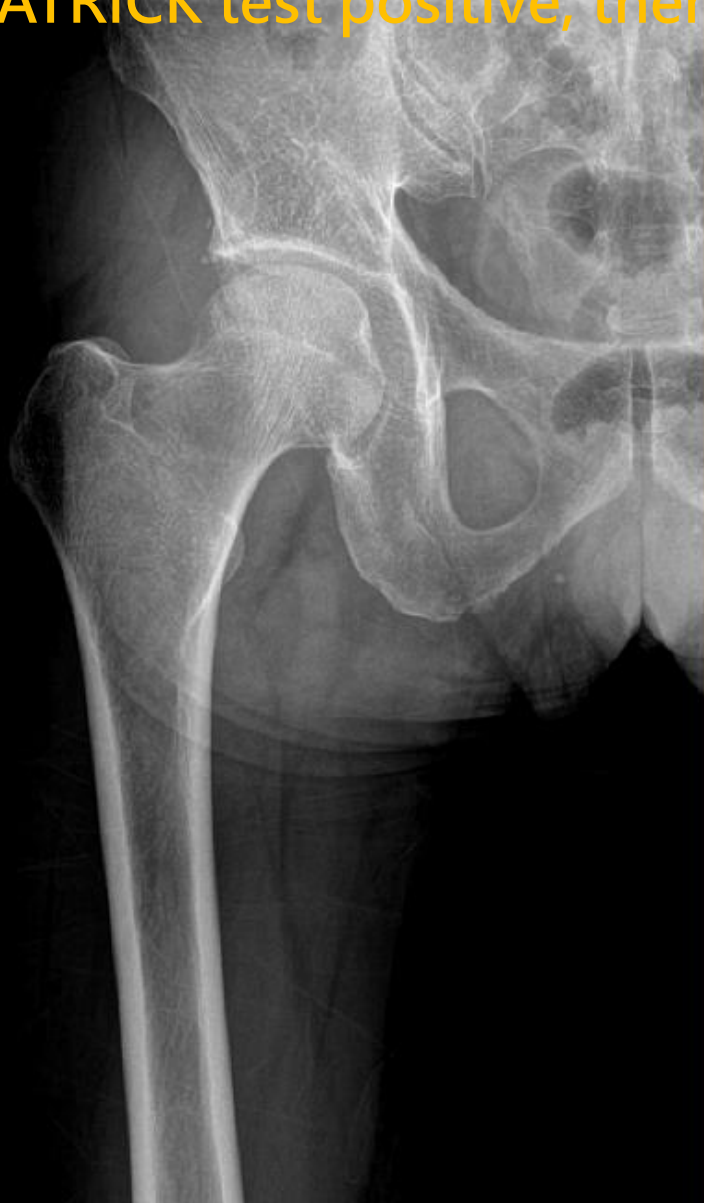2018-08-28 (門診)

63歲男性，三個禮拜前跌倒後右腕部疼痛，跛行
PATRICK test positive, then arrange ???

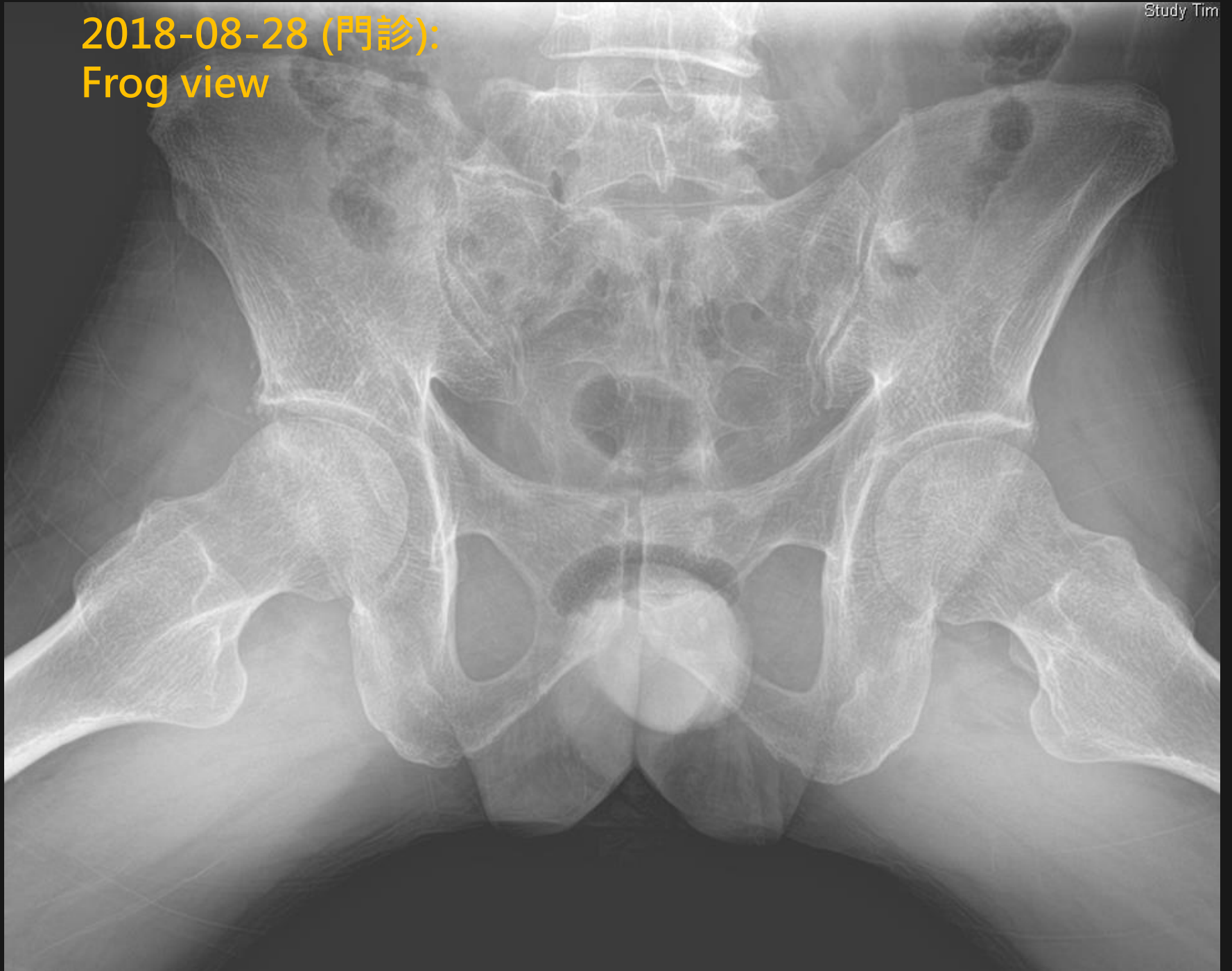
HUANG YUNG CHUEN
Study Date: 2018/8/28
Study Time: 下午 05:56:22
MRN: 0971130

Se: 1
Im: 2

HUANG YUNG
Study Date: 2018/8/28
Study Time: 下午 05:56:22
MRN: 0971130

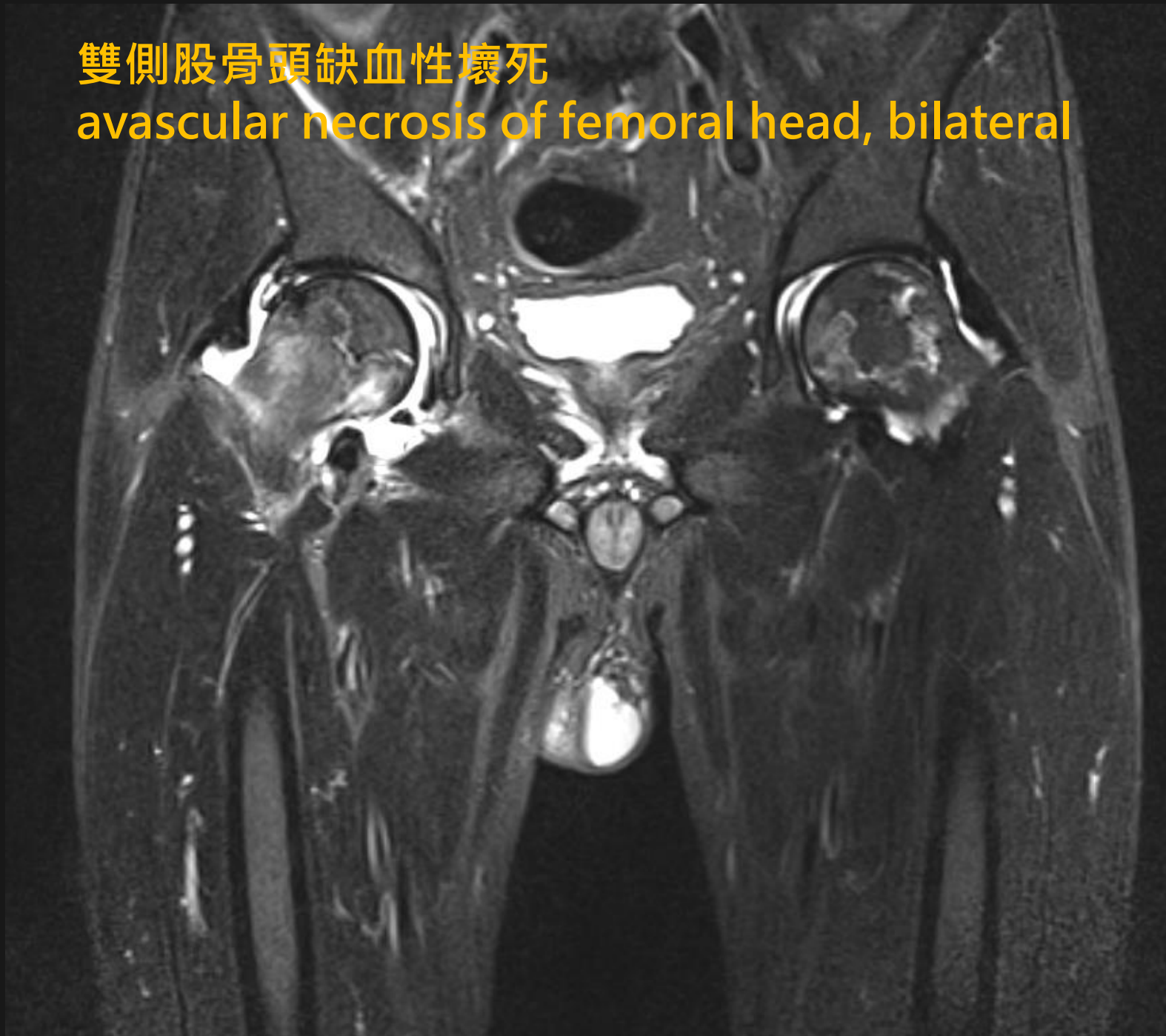


2018-08-28 (門診):
Frog view



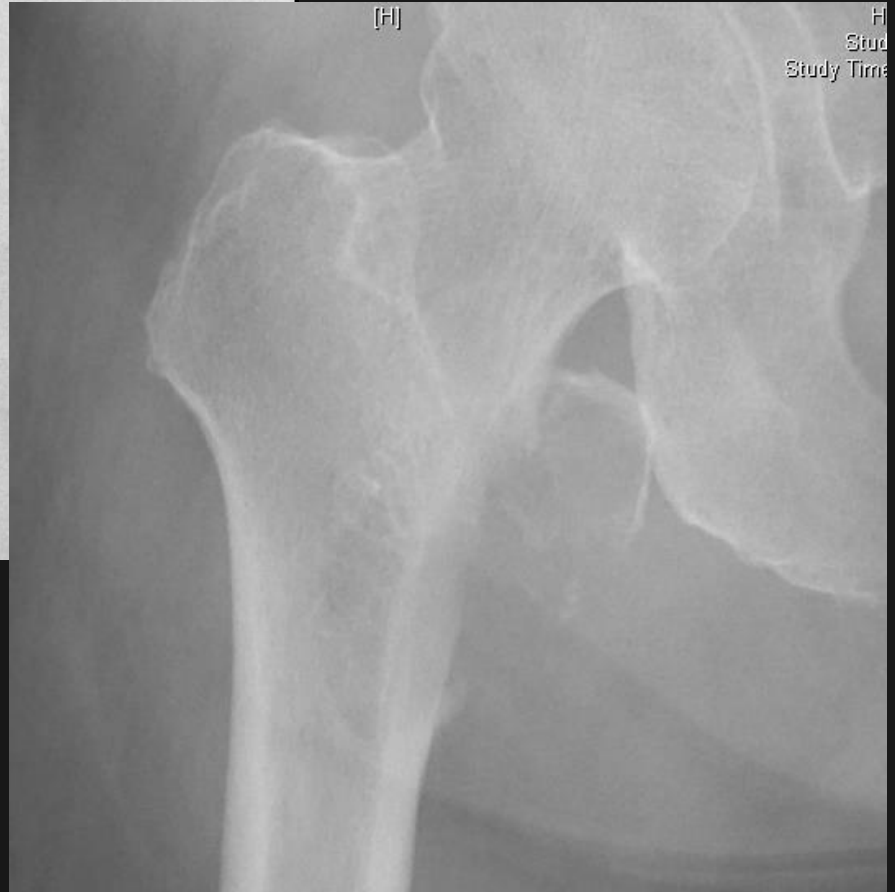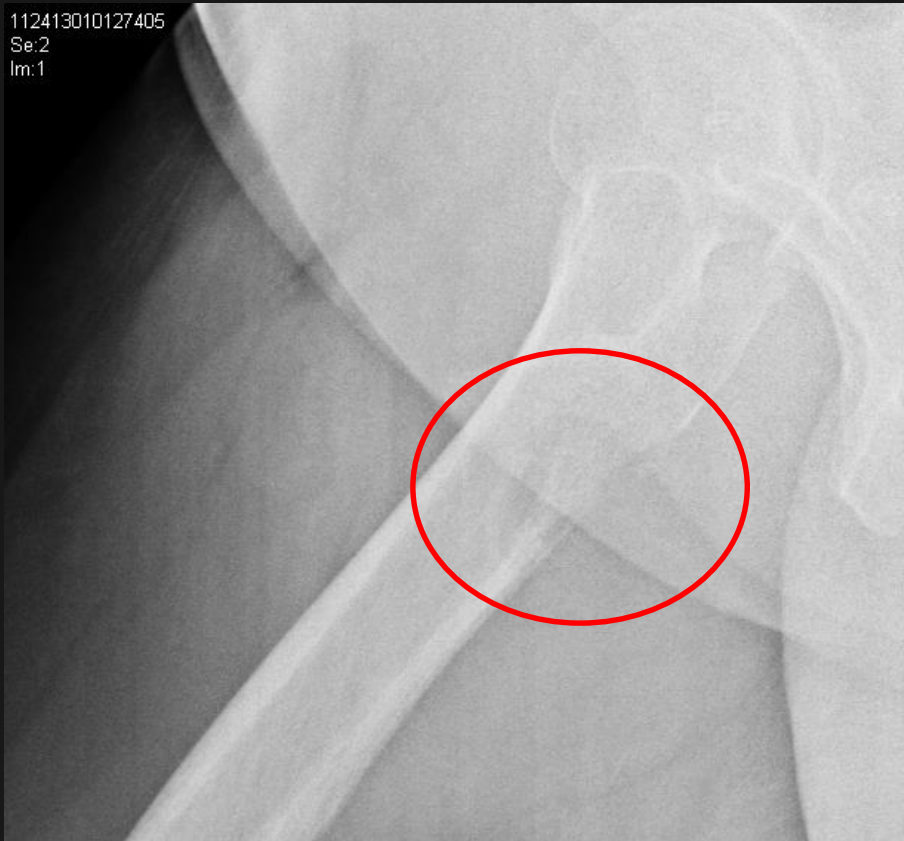
雙側股骨頭缺血性壞死

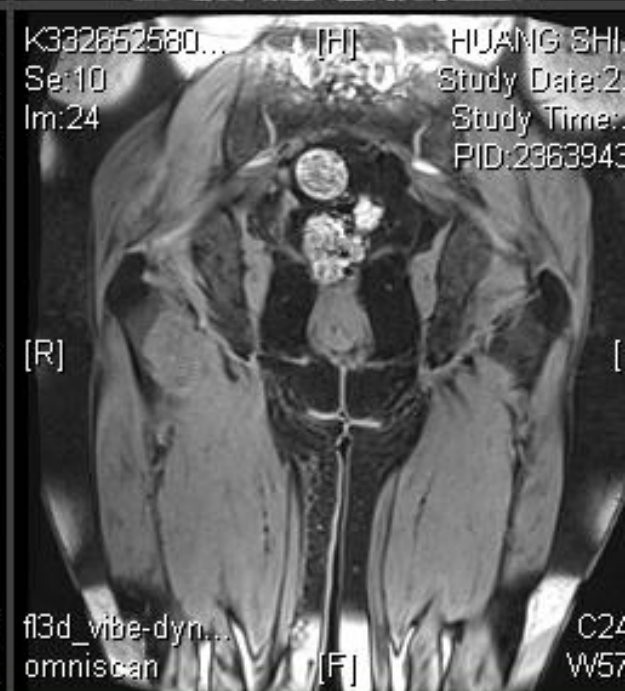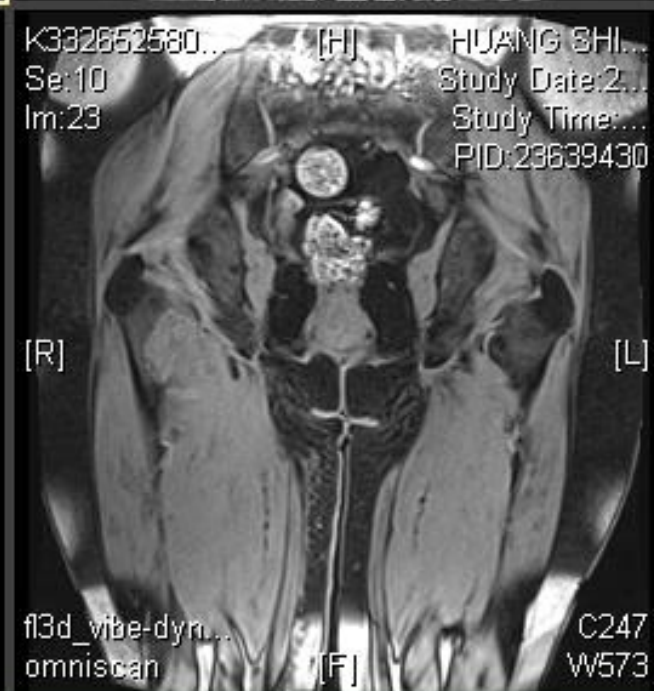
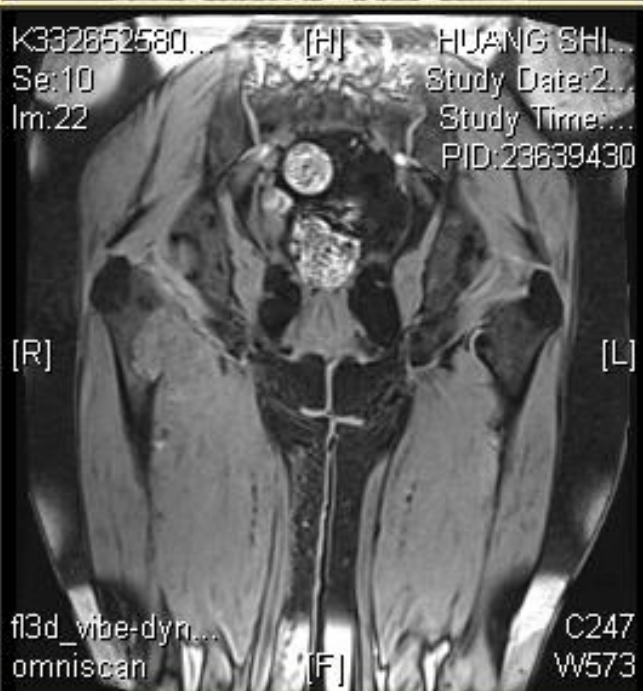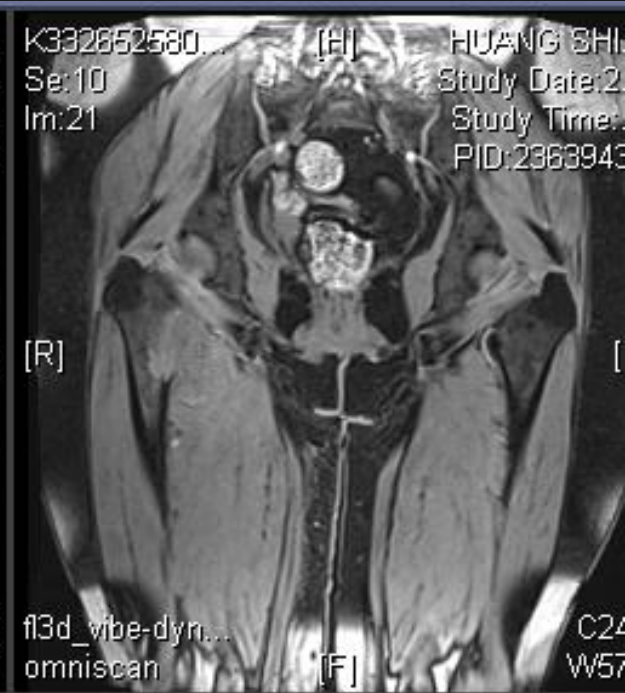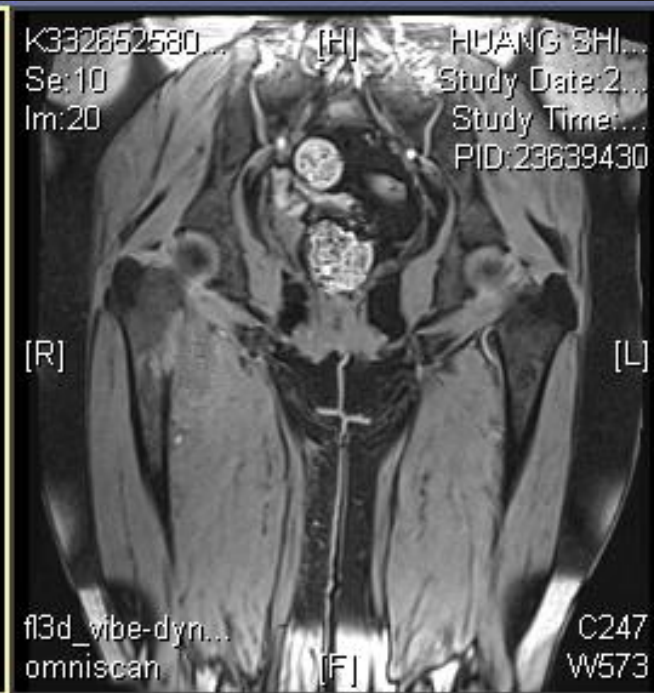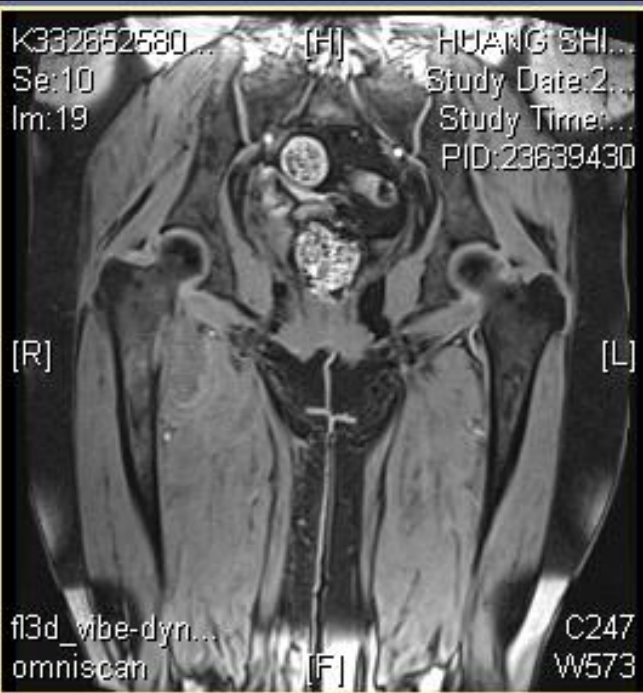avascular necrosis of femoral head, bilateral



112413010127405
Se:2
Im:1

HUANG SHIOU E
Study Date:2013/1/1
Study Time:上午 09:48:25
PID:M2528863

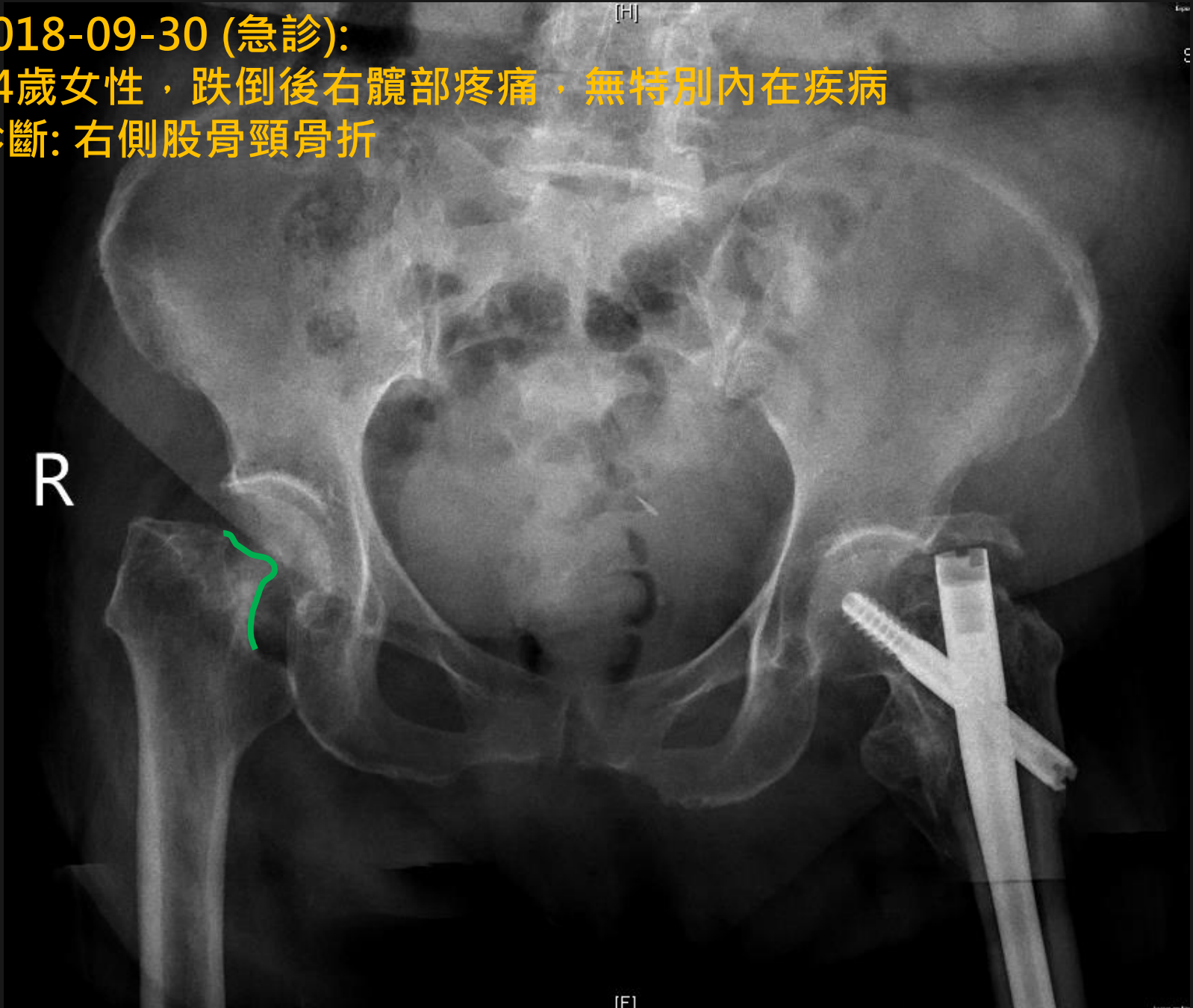




2018-09-30 (急診):

84歲女性，跌倒後右髖部疼痛，無特別內在疾病

診斷: 右側股骨頸骨折

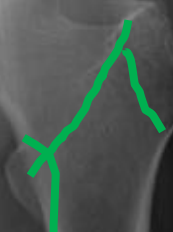

2018-08-16 (急診):

72歲女性，跌倒後右髖部疼痛，無特別內在疾病

診斷: 右側轉子間骨折

R



2018-10-05 (門診):
76歲男性，右髌部疼痛5天，沒有跌倒
有攝護腺癌合併骨轉移

Se:1
Im:1

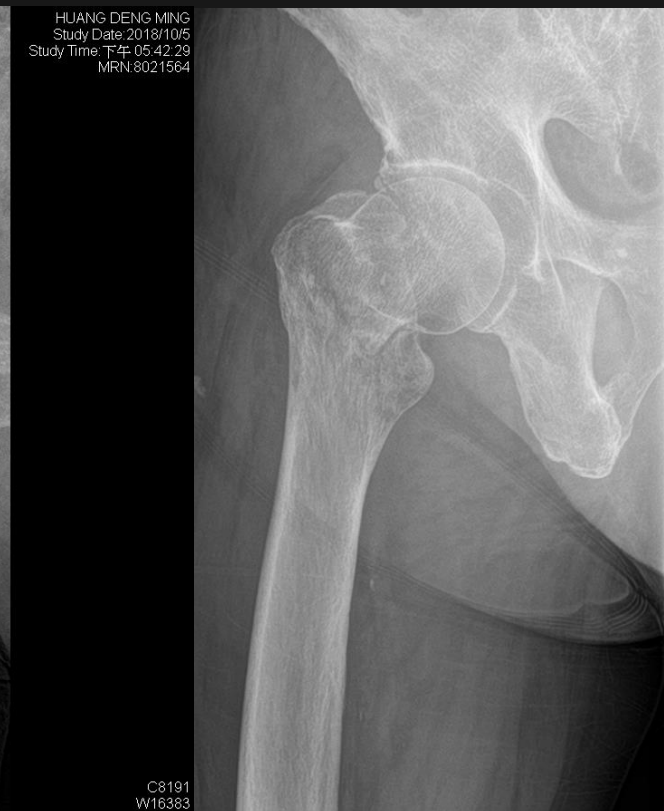
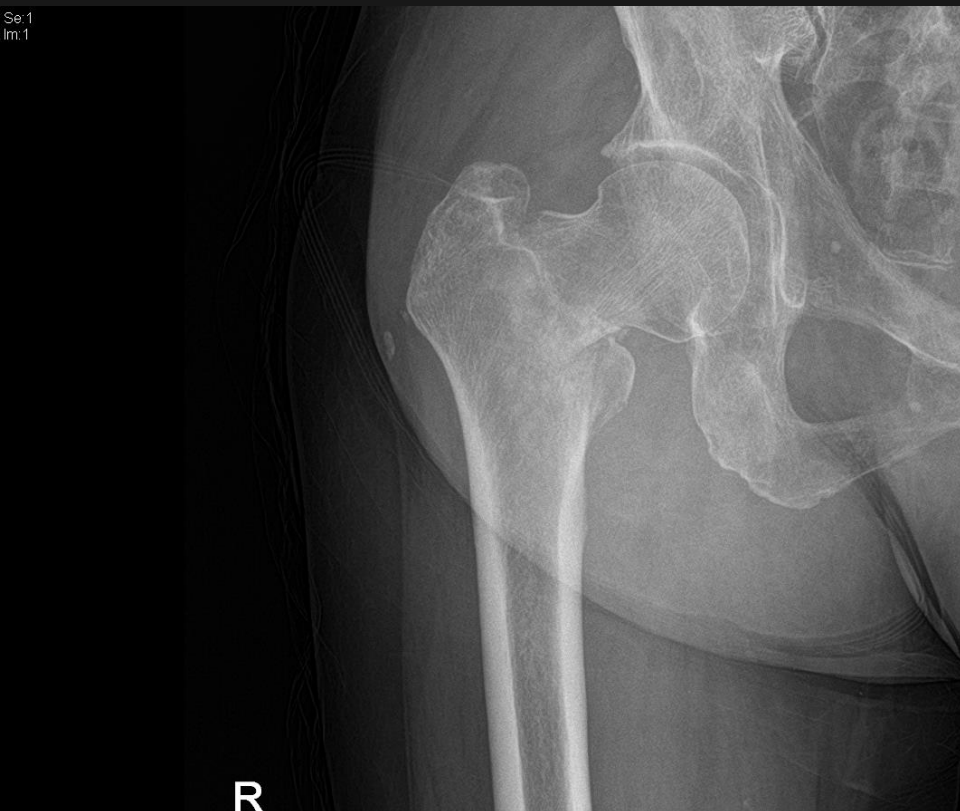
R

HUANG DENG MING
Study Date: 2018/10/5
Study Time: 下午 05:42:29
MRN: 8021564

C8191
W16383

HUANG DENG MING
Study Date: 2018/10/5
Study Time: 下午 05:42:29
MRN: 8021564

C8191
W16383



過去病史:攝護腺癌合併骨轉移

Se:
Im:0 (F1/1)

Workspace
BONE WB(L.Y.H)

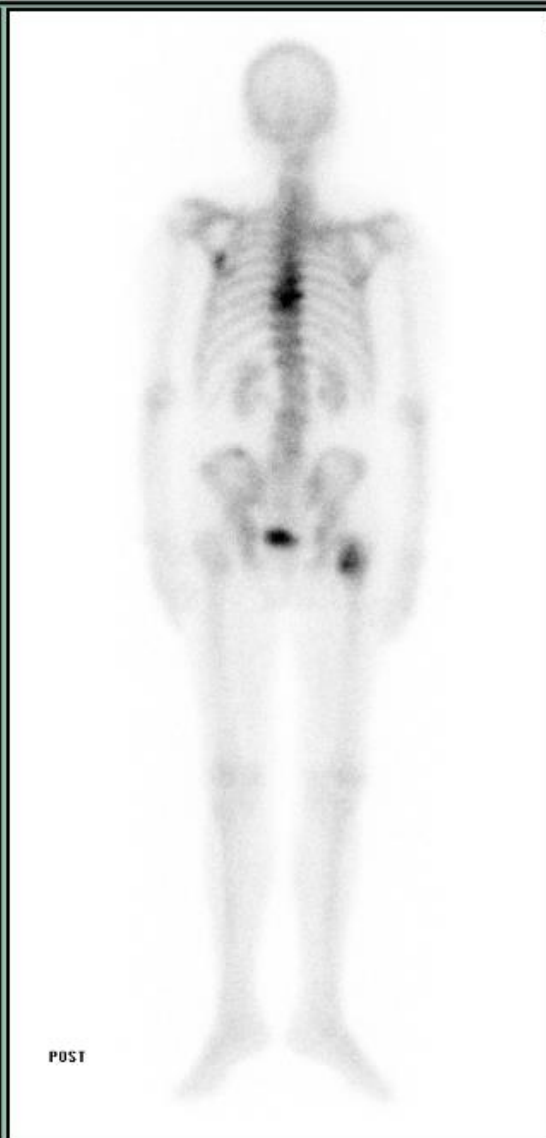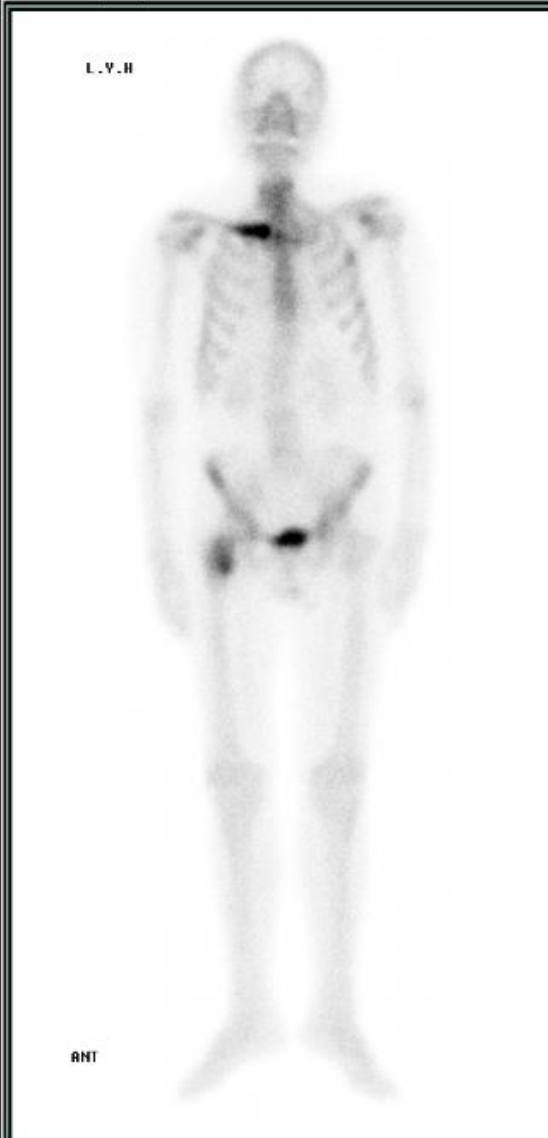HUANG DENG MING
8021564

WB BONE
9/26/2018 11:07

MILLENNIUM MG

Changhua Christian Hospital

HUANG DENG MING
Study Date:2018/9/26
Study Time:上午 11:03:54
MRN:8021564



Se:4
Im:15

HUANG DENG MING
Study Date:2018/10/6
Study Time:下午 07:17:08
MRN:8021564

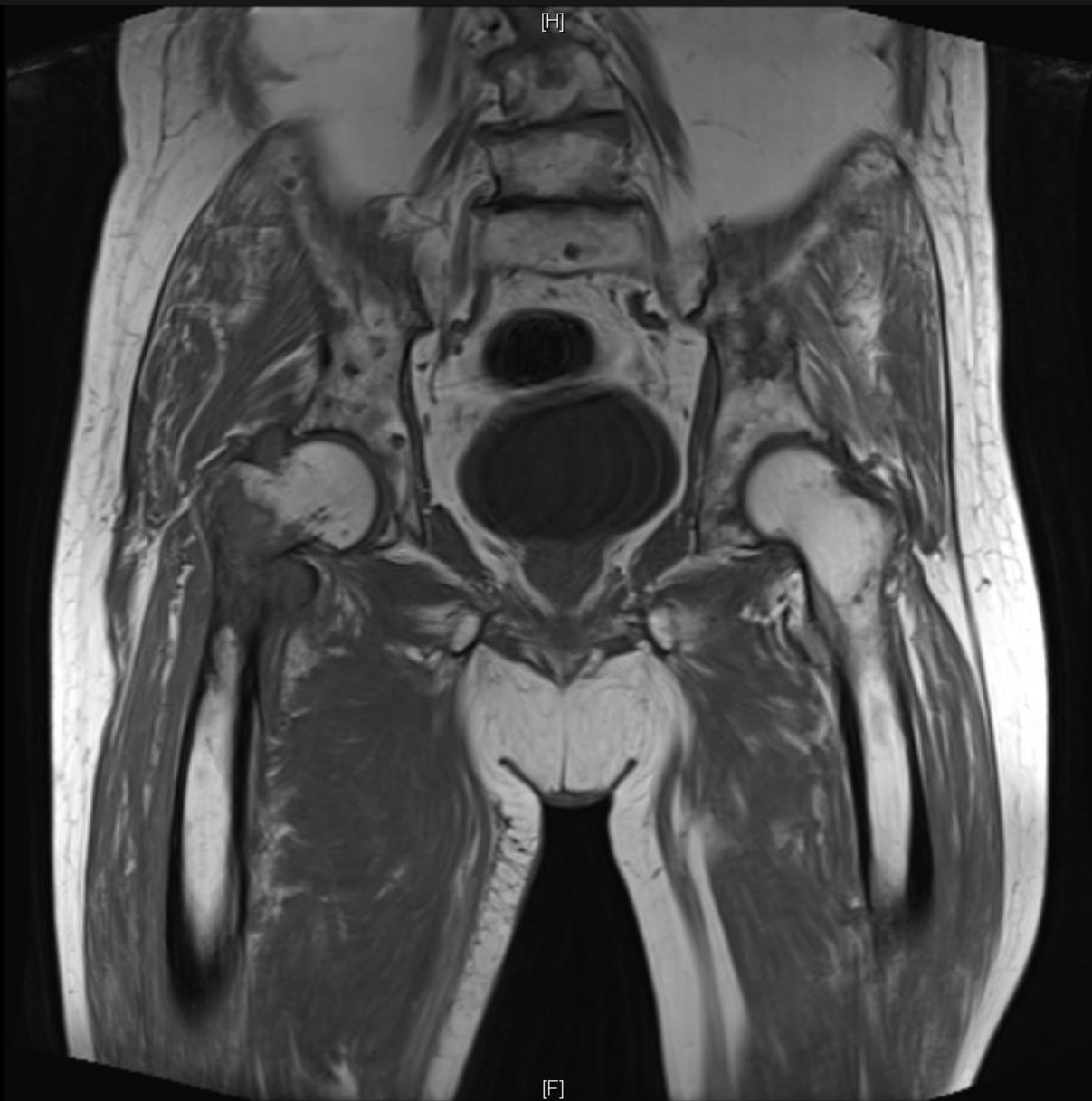
[R]

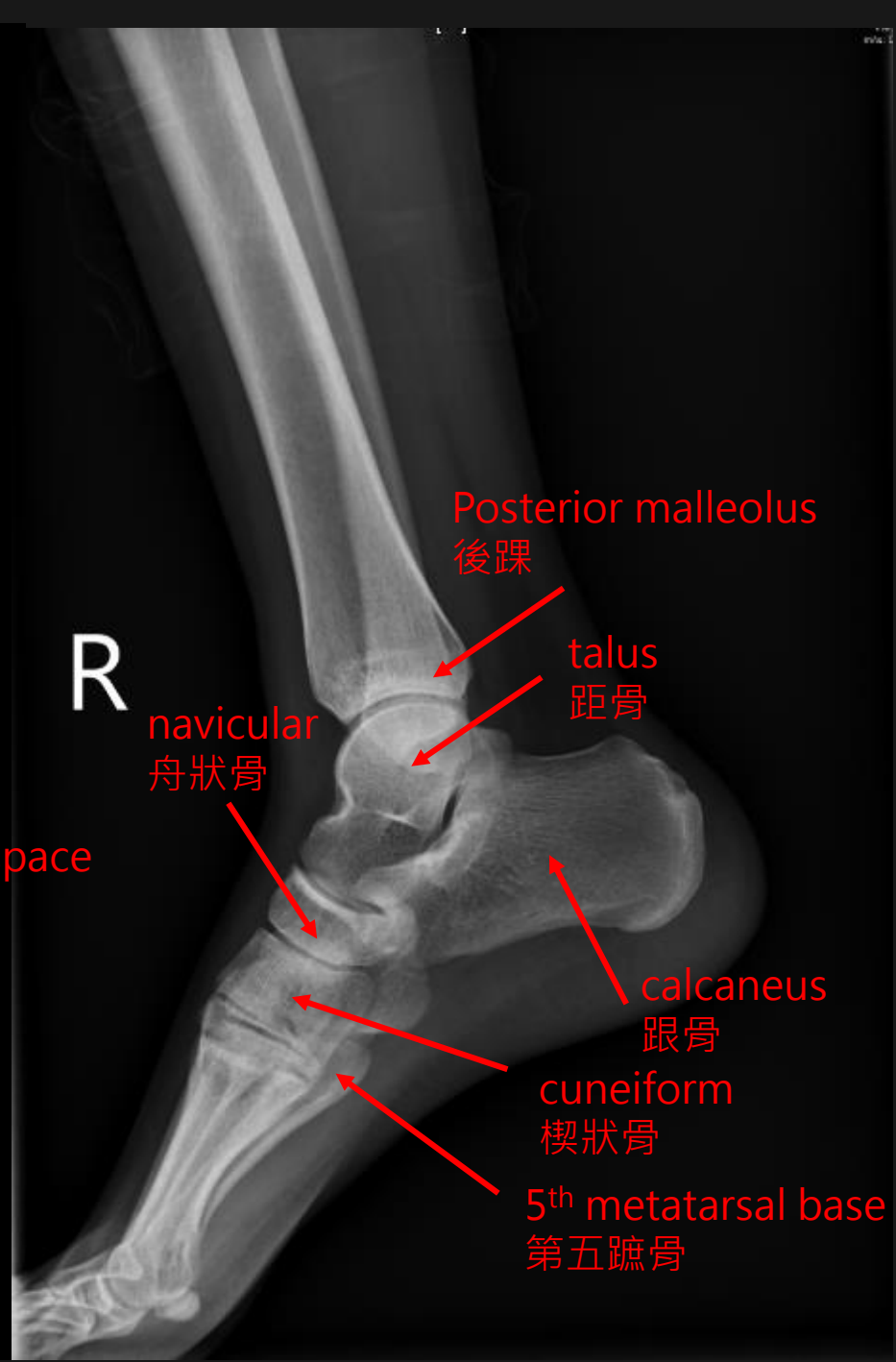
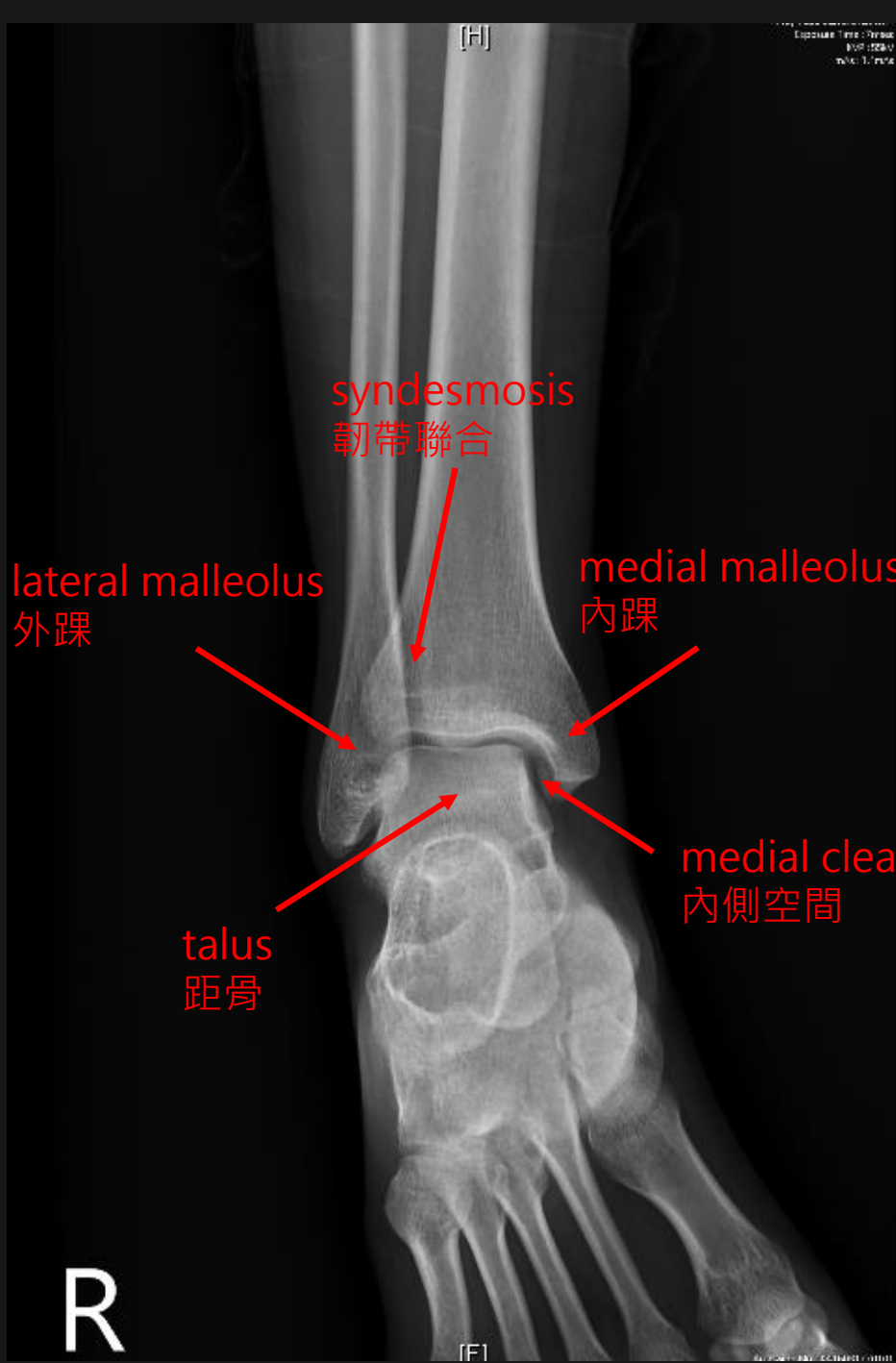
[L]

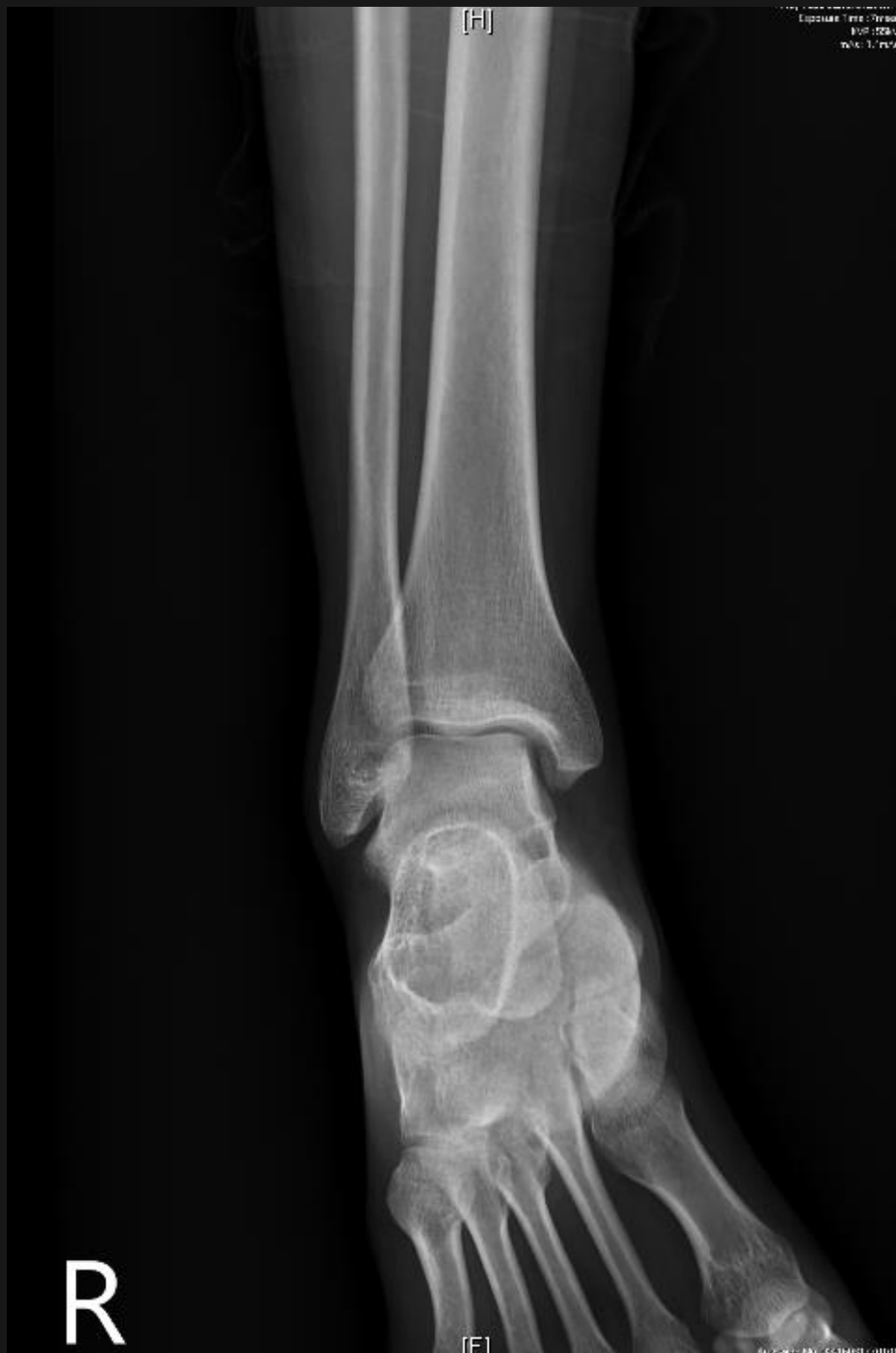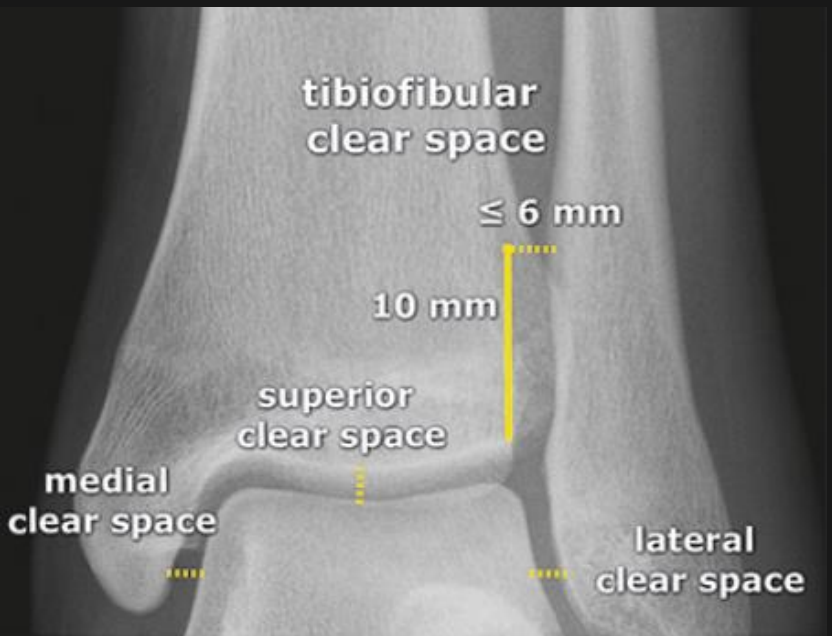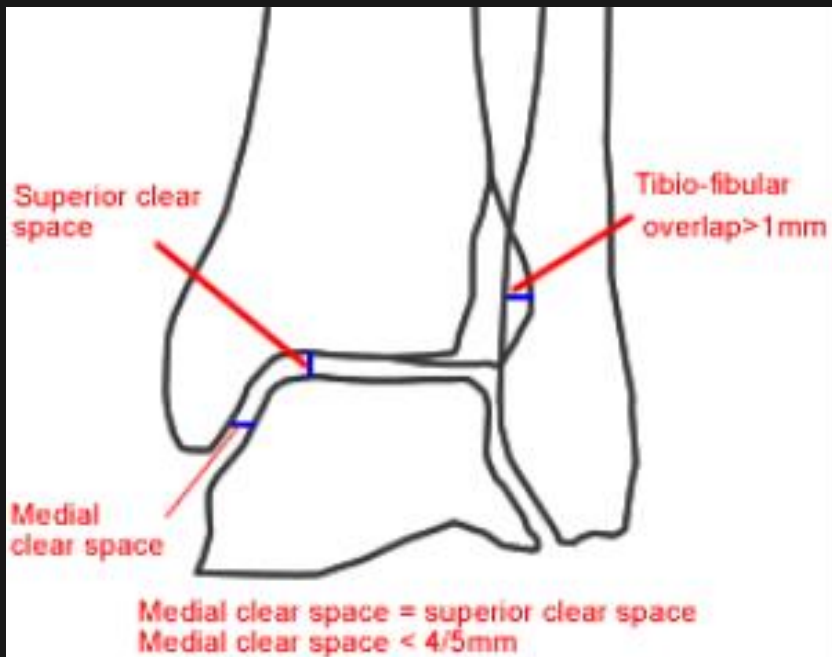
t1_tse_cor

[F]

C353
W762








R

2018-10-24 (門診):
27歲男性，跌倒扭傷腳踝，腫脹無法活動

syndesmosis
變寬

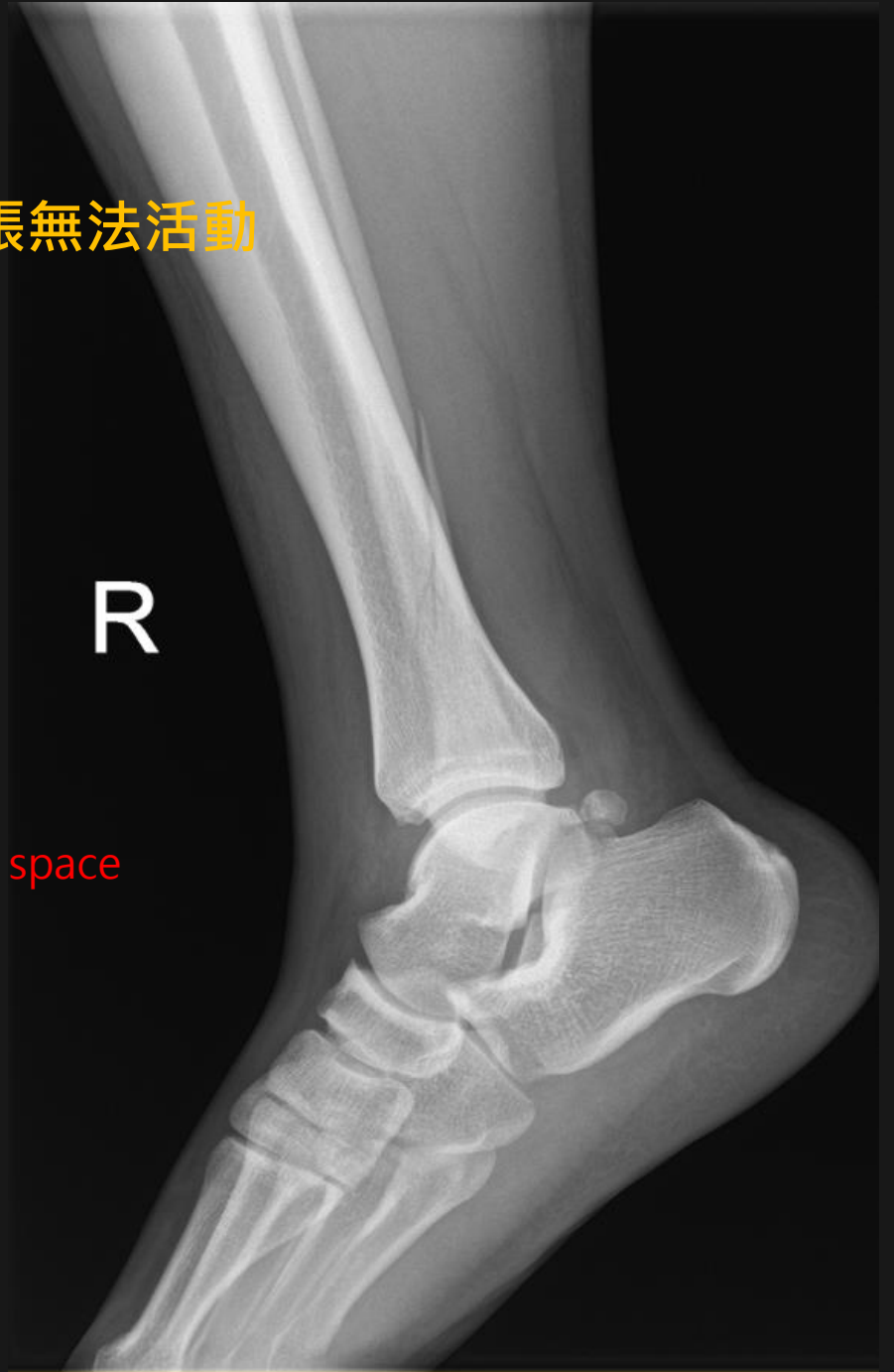


lateral malleolus
骨折

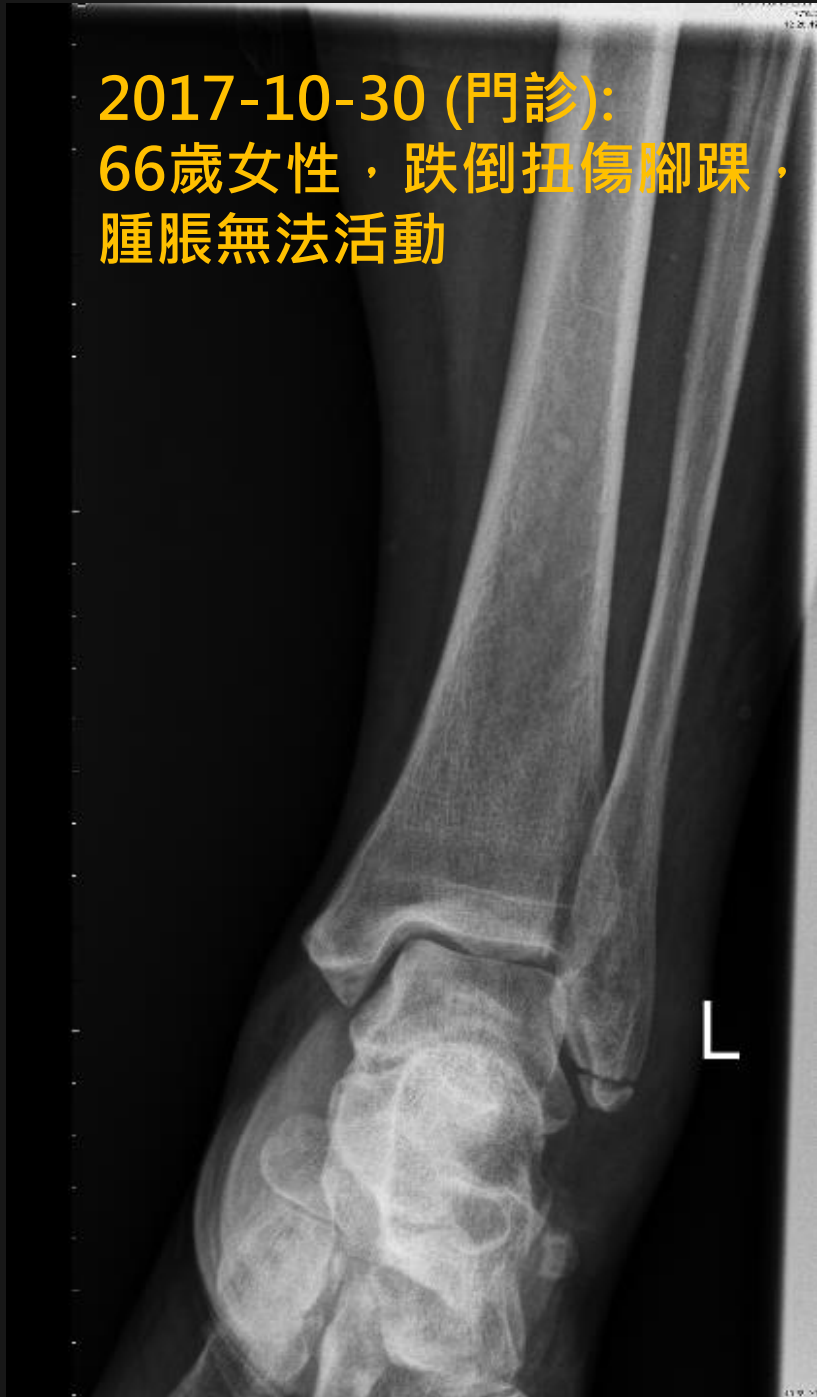

medial clear space
變寬

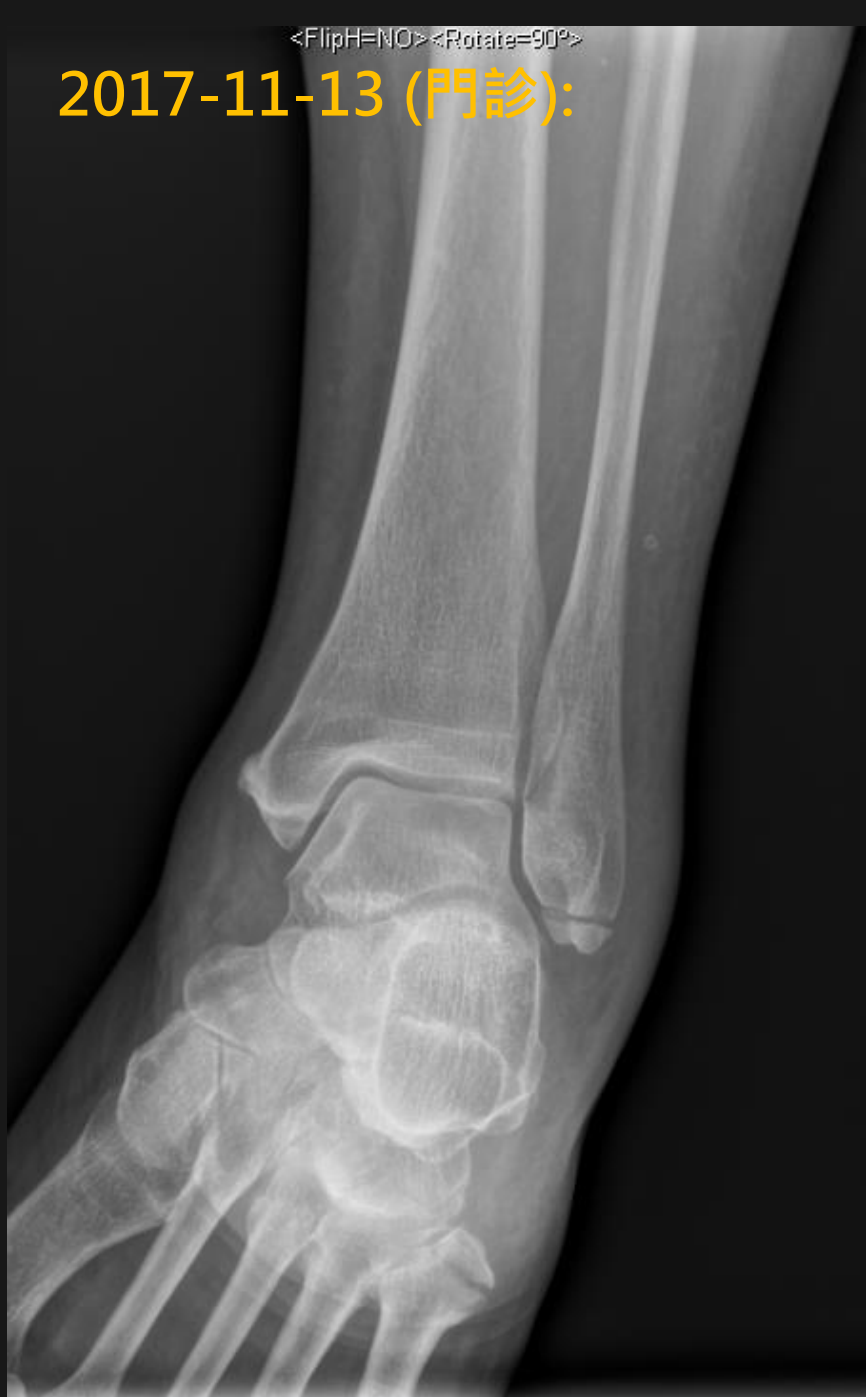R



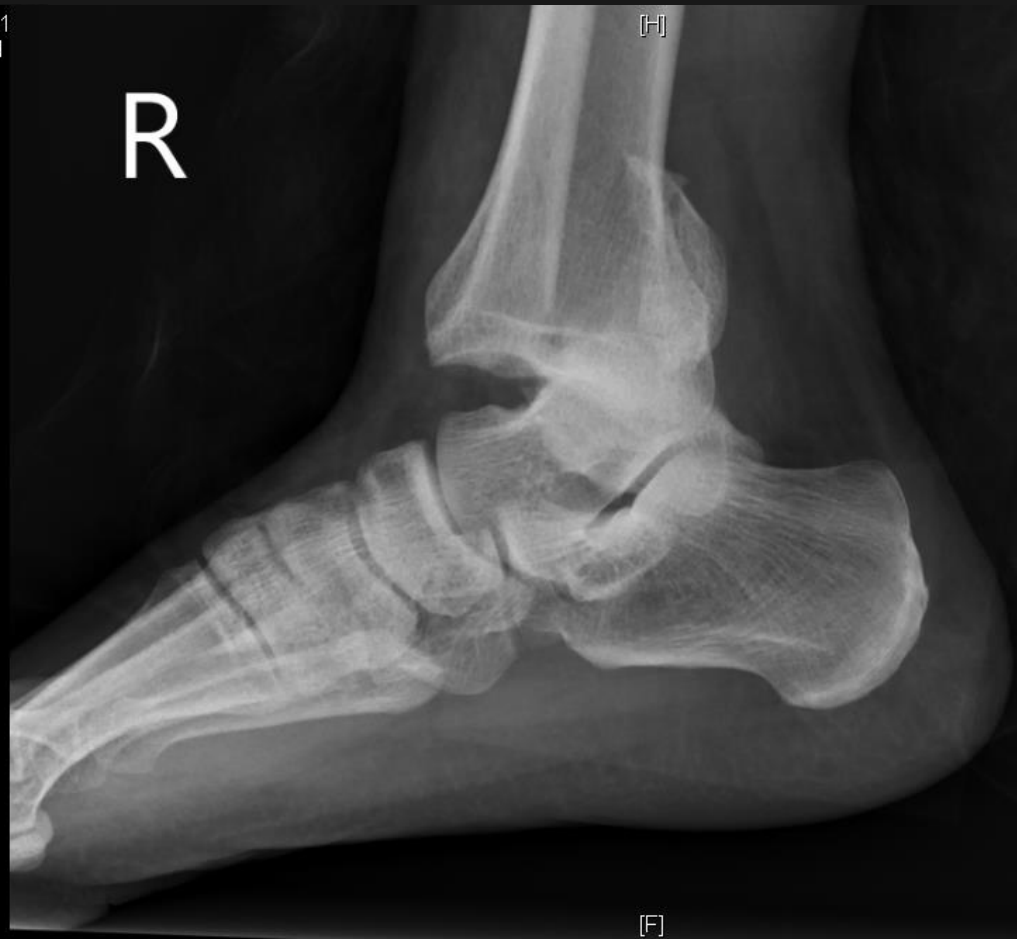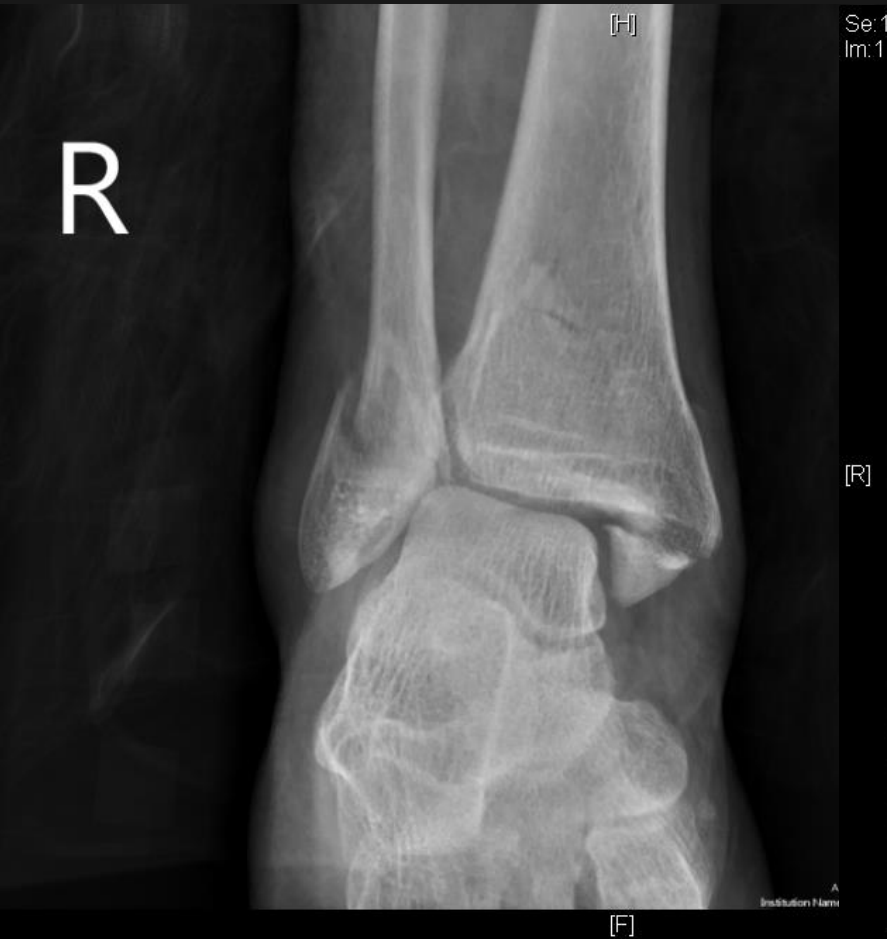2017-10-30 (門診):
66歲女性，跌倒扭傷腳踝，
腫脹無法活動



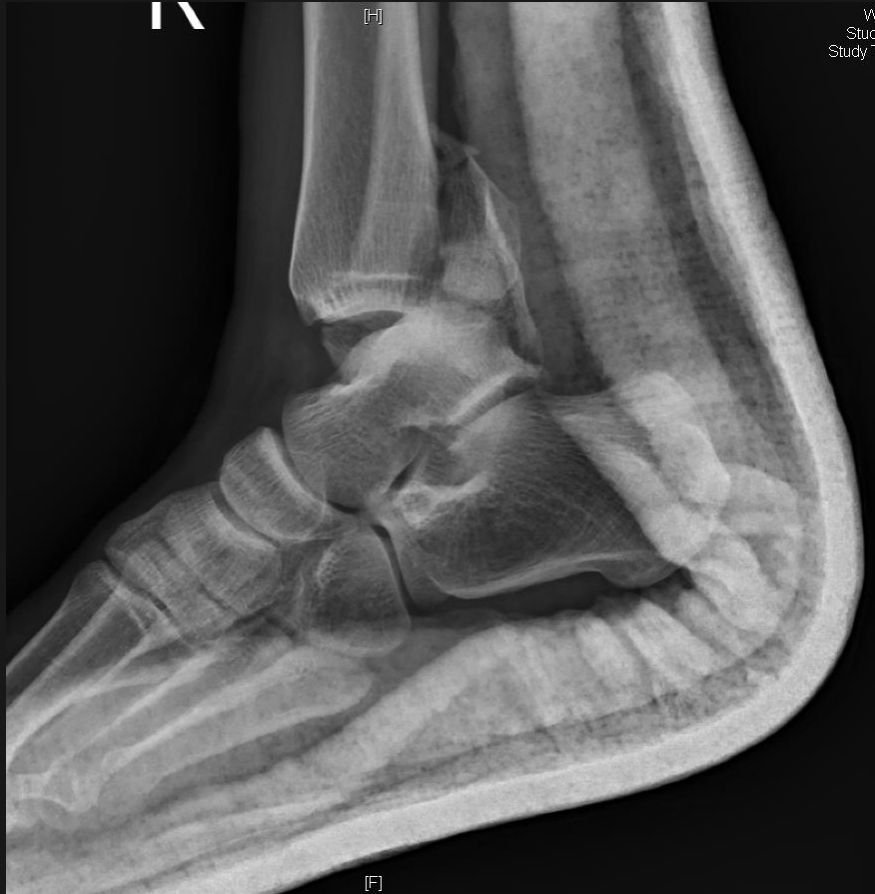<FlipH=NO><Rotate=90°>
2017-11-13 (門診):



2018-10-28 (急診):
48歲男性，跌倒扭傷腳踝，腫脹無法活動



第一次嘗試復位



第二次

